

# Cardiac surgery – Introduction Surgery of the aorta

---

László Hejmel MD, PhD

University of Pécs, Heart Institute

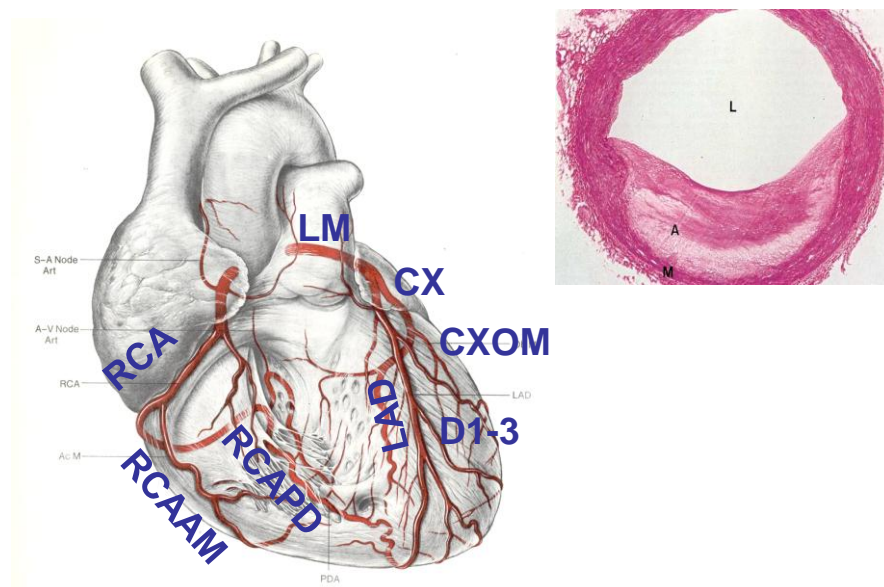
<http://aok.pte.hu/en/egyseg/oktatasianyagok/290>



Pécs, 2021

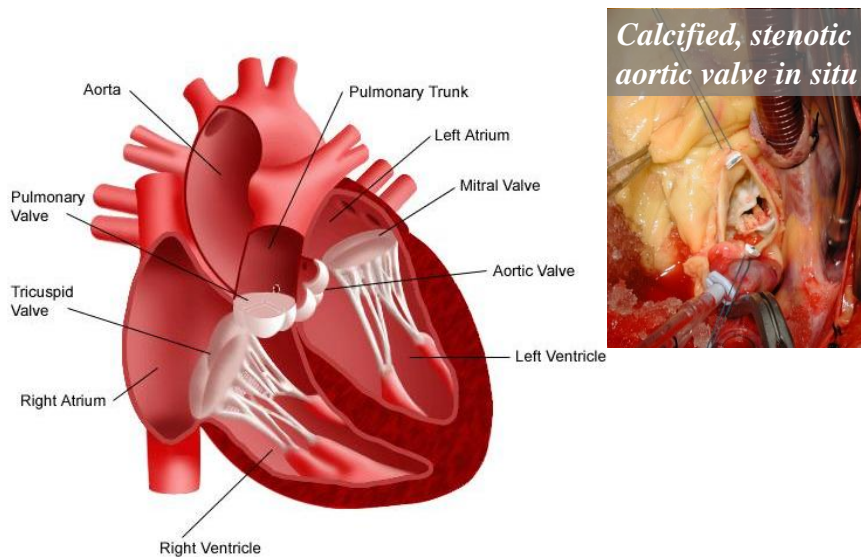
## The anatomy of coronary arteries

---



## The anatomy of the heart

---



## Most common types of heart operations

---

- coronary bypass grafting (CABG)
- valve replacement (AVR, MVR, TVR)
- valvuloplasty - repair (tricuspid, mitral – TVP, MVP)
- congenital (VSD, ASD, DBP...)
- operations on thoracic aorta (asc., arch)
- aneurysmectomy, aneurysm-plication
- heart transplantation and its alternatives
- pacemaker implantation

combined operations (CABG+valve, CABG+carotid endarterectomy, CABG+aneurysmectomy)

## Milestones of cardiac surgery

---



Theodore Billroth  
(1821-1894): *'Any surgeon who would attempt operation on the heart should lose the respect of his colleagues'*.



Ludwig Wilhelm Carl Rehn  
(1849-1930)  
First successful myocardial suture: **1896**

## The requirements for modern cardiac surgery

---

- diagnostic background (coronarography, echo)
- asepsis, antibiotics
- transfusiology
- hemostaseology
- anesthesiology - intensive care
- extracorporeal circulation
- myocardium protection
- operative technique
- artificial valves, other prostheses

## Milestones in cardiac surgery

**1896. Rehn (G, 1849-1930) successfully sutures a heart wound**

**1925. Souttar (UK, 1875-1964) – closed mitral commissurotomy**

**1928. Forssmann (G, 1904-1979) – first cardiac catheterization via cephalic vein on himself**

**1939. Gross (USA, 1905-1988) – ligation of ductus Botalli**

**1950-s Gibbon, Kirklin, Lillehei - ECC**

**1951. Vineberg a. thoracica interna implantation**

**Favaloro, Effler v. saphena bypass**

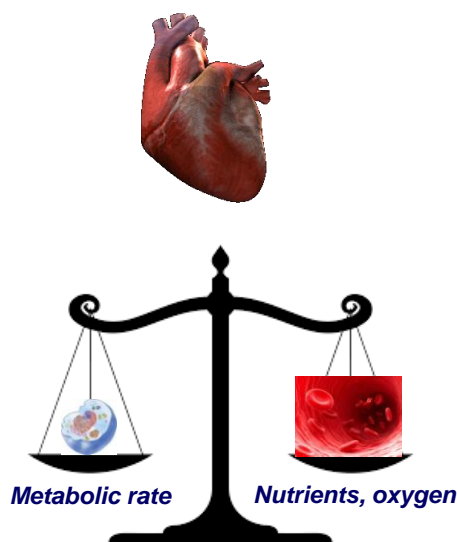
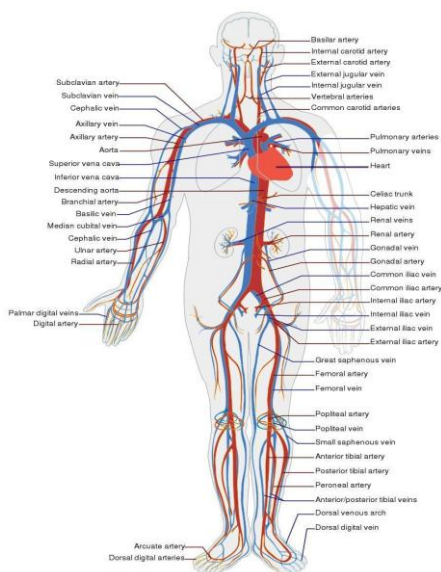
**1953. ASD operation**

**1955. VSD operation**

**1964. Kolesov a. thoracica interna-LAD bypass**

**1968. Green a. thoracica interna-LAD bypass**

## The circulation – ischemic damage



## The making of the heart-lung machine







Fig 2. Photograph taken in Dr Gibbon's laboratory, showing an early version of his heart-lung machine. (Courtesy of J. H. Gibbon, Jr. Reprinted with permission from Gibbon JH et al. Arch Surg. 1937; 34:1109.)

**John Gibbon  
(1903-1973)**



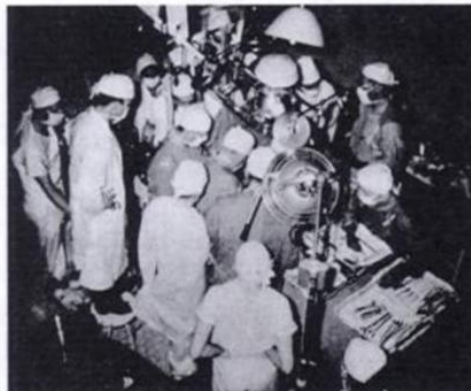**May 6th 1953.** The first successful ASD closure with the usage of heart lung machine (IBM).

## Hypothermia – other arm of the scale




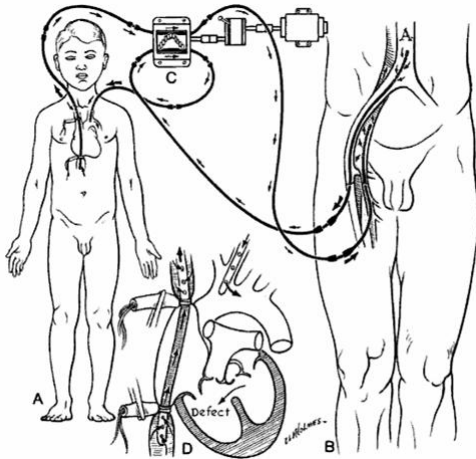
**JF Lewis (1916-1993)**

**1953.** Lewis and Taufic: Closure of atrial septal defects with the aid of hypothermia. in Surgery



**Sept. 2nd 1952.** The first open heart surgery, 2 cm ASD-II closure in a 5 year old girl,  $t=26^{\circ}\text{C}$  full body hypothermia, with inflow stasis. (University of Minnesota Hospital)

# „Cross-circulation”



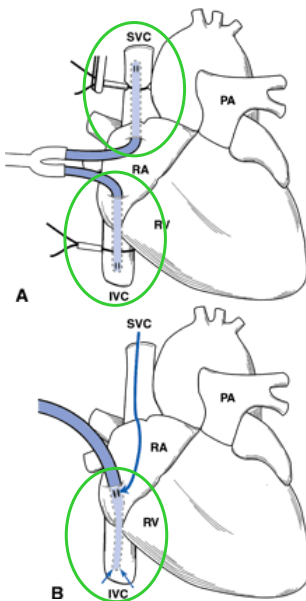
**CW Lillehei (1919-1999)**

*Lillehei-Cohen-Warden*

*Hard criticism...*

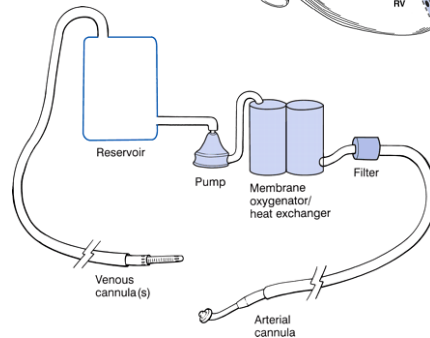
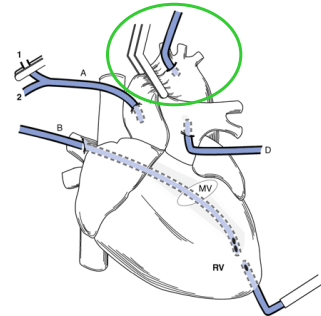
**1954-55: 45 open heart surgeries: VSD, AV-canal, Fallot-IV. Eg.: F-IV 14 minutes cross-circulation time.**

## The schematic of extracorporeal circulation

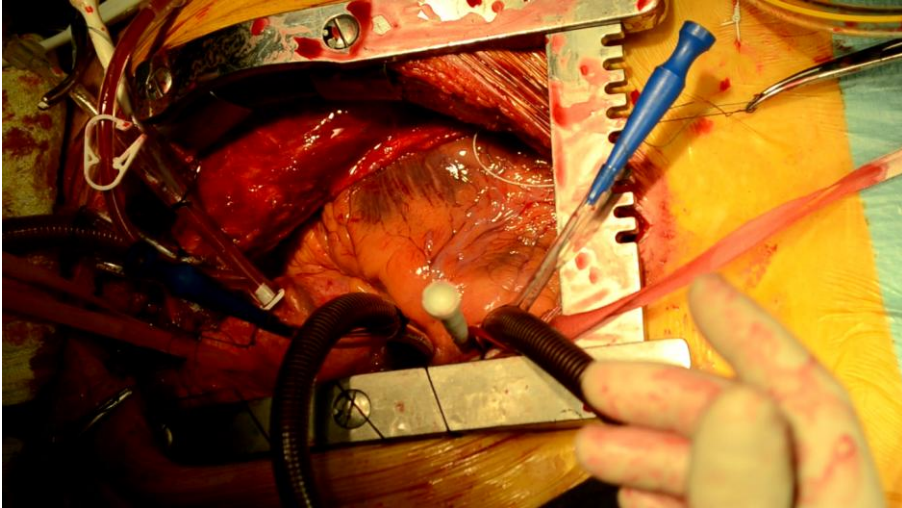


**Heparinization:**  
300NU/bwtkg  
*Na-heparin*

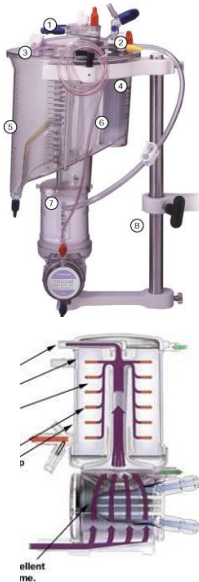

**Antidote:**  
*Prothamin*



## The cannulation in real life



## The modern heart-lung machine



- roller pump (2)*
- reservoir (1)*
- bubble trap (5)*
- oxygenator (3)*
- heat exchanger (4)*
- tubing*

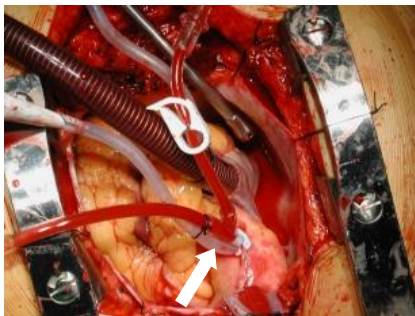
## The pathophysiology of the ECC

---

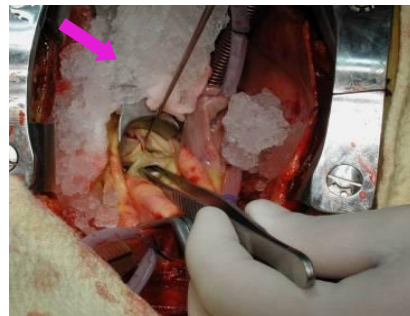- *hemodilution*
- *locoregional malperfusion*
- *acidosis*
- *inflammatory response, complement activation*
- *capillary leakage*
- *actions of hypothermia (Hb oxygen binding properties, enzyme activity, hemostasis, etc.)*
- *disruption of blood cells*
- *metabolic, endocrine changes*
- *electrolyte disturbances*

## Myocardial protection

---



*anterograde aortic root  
cardioplegia and vent*



*local ice-squash*

*Myocardial protection by administering a special cold solution into the coronary circulation. The most popular: +4 °C hyperkalaemic crystalloid cardioplegia, that causes depolarization block, arrest, sparing the energy expenditure of contraction and electric activity.*



## Myocardial protection

---

### anterograde

aortic root  
direct ostial

### retrograde

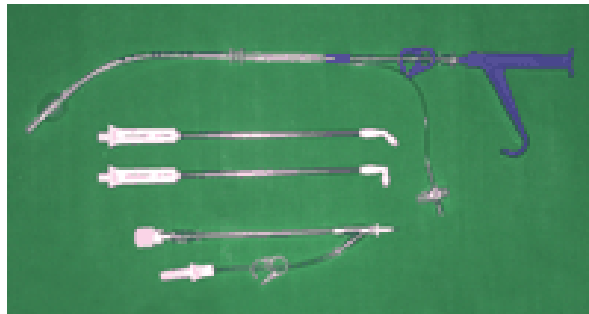
sinus coronarius

### anterograde-

-retrograde

crystalloid - blood

cold - warm cardioplegia



## The diagnosis of heart diseases

---

History: angina, dyspnea, fatigue

Physical changes: primarily not present in CAD, murmurs

Tests: ECG, stress ECG, Holter (silent ischaemia)

Echocardiography (transthoracic, transesophageal)

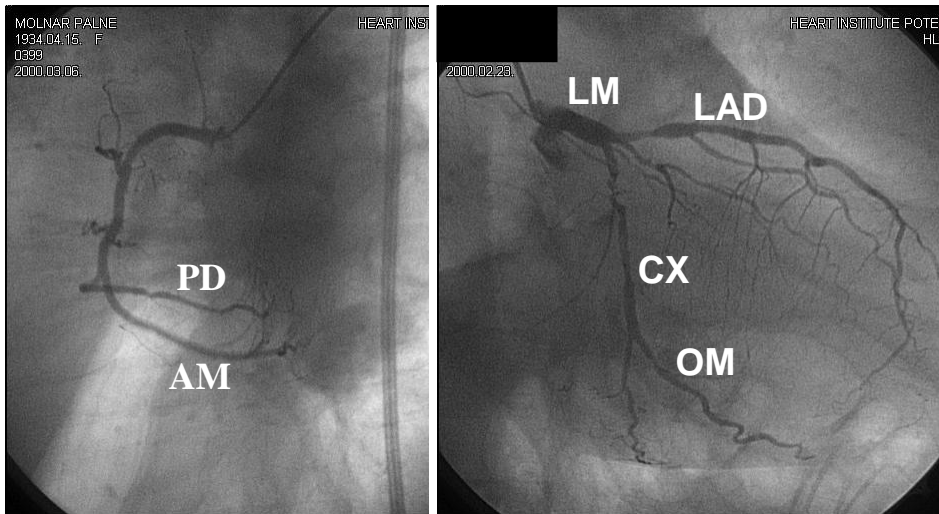
(Myocardium perfusion: scintigraphy, SPECT)

**Coronary angio**: above 40 years before each cardiac surgery  
Coronary CT (or at suspicion of IHD)

Viability examinations: MRI, (PET)

Biopsy

## Coronary angiography



## Preoperative examinations, preparation

- investigating cardiac status, stabilizing patient
- above 40 years coronary angiography
- screening and treating foci  
(dental, ENT, urology/gynecology)
- chest X-ray, abdominal ultrasound
- carotid Doppler or carotid angiography
- specialist at any comorbidity or suspicion! (vascular surgeon, colonoscopy, gastroscopy, endocrinology, etc.)
- **discontinuing oral anticoag., anti-TCT, metformin**

## Follow-up for CABG

---

Cardiac surgery control at 6-8 weeks: complaints, wound healing, sternum stability, ECG, Echocardiography

Cardiology control every 6 months or annually (ECG, stress test, Echocardiography), on demand interventional or cardiac surgical control, see family physician

Anti-platelet drugs life-long, if should be stopped before any intervention → administer LMWH

Secondary prevention: lifestyle, diet, drugs (statin, anti-TCT,  $\beta$ -blocker, etc.)

## Patient follow-up after valve op.

---

**Anticoagulation:** Syncumar/Cumadine to INR

**Biograft:** 3-6 months (INR 2.0-3.0), then ASA

**Mechanical:** life-long (Ao: 2.0-3.0, M: 2.5-3.5)

**Tell it before any medical intervention !**

**1 week before any operation change to LMWH**

**postoperatively heparine for some days**


**Endocarditis profilaxis:** antibiotics

**In case of dental extraction (deputation) or before and after any invasive intervention**

**amoxicillin+clavulanic acid, erythromycin**

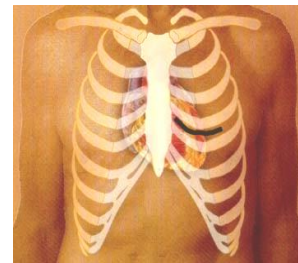
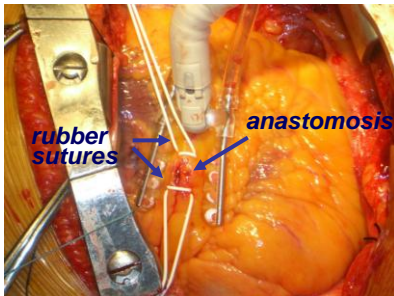
## Minimally (less) invasive directions

### „off-pump” CABG MIDCAB



Stabilizing LAD

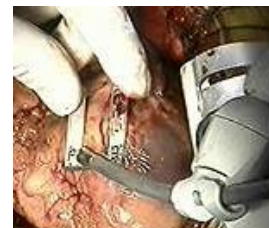Octopus, Medtronic, Inc.



## Off-pump CABG operations

- avoids complications of ECC
- however, hypoperfusion ↑
- still manipulations on asc. aorta

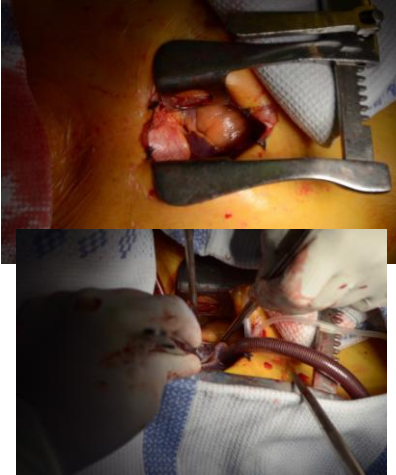- need for special stabilizing device
- occluder or shunt occluder
- sometimes difficult access of coron.
- cannot open heart chamber
- operative manipulation affects cardiac output



## Minimally invasive access

---

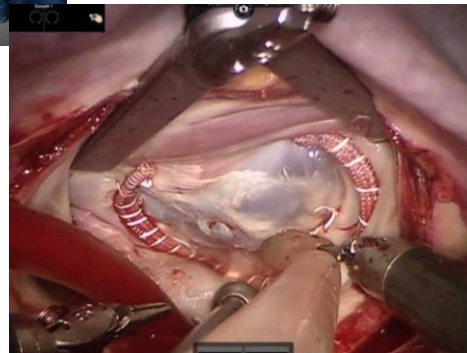
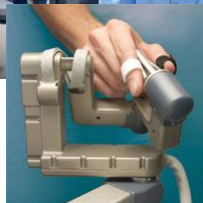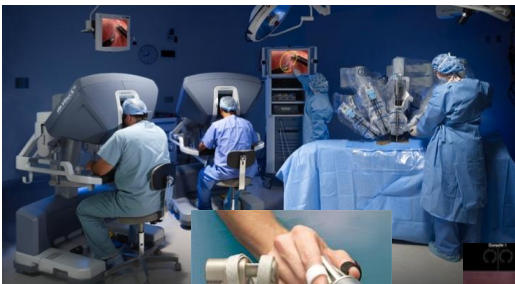
- smaller (even 4-6 cm!) skin incision
- minimal tissue damage, intact chest wall



- less operative stress
- shorter operation (?)
- less complications (?)
- less postop. pain
- shorter physical recovery
- early rehabilitation
- **better cosmetical results**
- reduced costs (?)

## Robot-assisted surgery

---



- Mitral valve repair
- CABG
- PM electrode implant.
- etc.

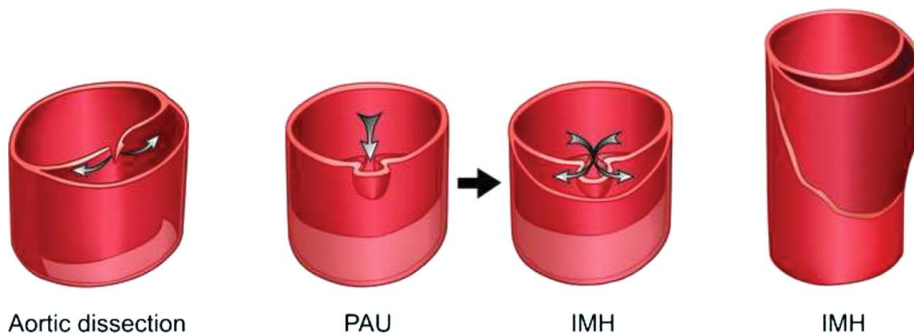
## Aortic diseases

---

- Atherosclerosis
- Aneurysm (saccular, fusiform,  $\geq 150\%$  normal diam.)
- Dissection: intimal tear, flap, helical pseudo lumen  
(acute < 2 weeks, subacute, chronic > 6 weeks)
- Transsection (traumatic, due to deceleration, prox. DA, dist. AA)
- Rupture: bleeding to mediastinum, bronchi, pleura, pericardium (tamponade!)
- Aortitis (S. aureus, Salmonella, syphilis, Takayashu, Giant cell)
- Penetrating atherosclerotic ulcer (PAU)
- Intramural haematoma (IMH, from vasa vasorum)
- Acute aortic syndrome (acute dissection, PAU, IMH)
- Aortic regurg. (annular dilation, rupture, dissection)

## Acute Aortic Syndrome

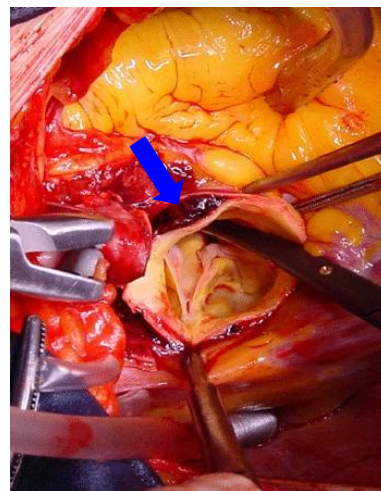
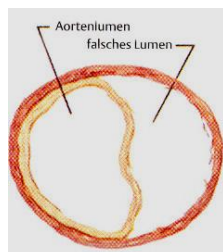
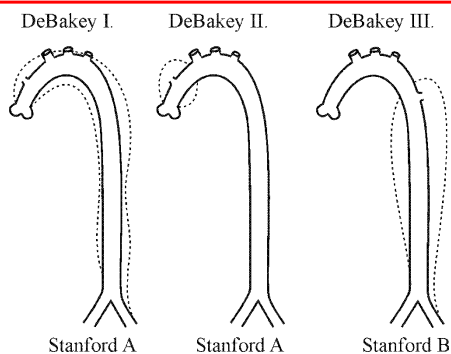
---



## Acute aortic dissection

- 2-3.5 cases/100 000 persons/year
- Symptoms: chest pain, hoarsness, focal ischaemia, bleeding, hypovolaemia, shock, tamponade, AI→pulm. Edema, embol.
- Diagnosis: Echo, CT, MRI, TEE, D-dimer (?!)
- Spontaneous mortality:
  - asc. included: 35% at 1 day, 50% at 2 days, 70% at 1 week
  - desc.: 90% survival at 1 month
- Treatment:
  - initial medical: (dP/dt↓, SBP<100-120mmHg, pulse:60-80/min)
  - β-blocker, nitrate, opiate
  - acute ascending – emergency operation
  - desc – medical treatment unless ischaemic signs occur

## Aortic dissection



### Recommendations for Asymptomatic Patients With Ascending Aortic Aneurysm

1. Asymptomatic patients with degenerative thoracic aneurysm, chronic aortic dissection, intramural hematoma, penetrating atherosclerotic ulcer, mycotic aneurysm, or pseudoaneurysm, who are otherwise suitable candidates and for whom the ascending aorta or aortic sinus diameter is **5.5 cm** or greater should be evaluated for surgery

2. Patients with Marfan syndrome or other genetically mediated disorders (vascular Ehlers-Danlos syndrome, Turner syndrome, bicuspid aortic valve, or familial thoracic aortic aneurysm and dissection) should undergo elective operation at smaller diameters (**4.0 to 5.0 cm** depending on the condition; see Section 5) to avoid acute dissection or rupture.

3. Patients with a **growth rate of more than 0.5 cm/y** in an aorta that is less than 5.5 cm in diameter should be considered for operation.

4. Patients undergoing **aortic valve repair** or replacement and who have an ascending aorta or aortic root of greater than **4.5 cm** should be considered for concomitant repair of the aortic root or replacement of the ascending aorta.

### Recommendation for Symptomatic Patients With Thoracic Aortic Aneurysm

1. Patients with symptoms suggestive of **expansion** of a thoracic aneurysm should be evaluated for prompt surgical intervention unless life expectancy from comorbid conditions is limited or quality of life is substantially impaired

- TEE (semiinvasive)
- CT (ECG-gated)
- MRI (ECG gated)

### Recommendations for Aortic Arch Aneurysms

1. For thoracic aortic aneurysms also involving the proximal aortic arch, partial arch replacement together with ascending aorta repair using right subclavian/ axillary artery inflow and hypothermic circulatory arrest is reasonable.

2. Replacement of the entire aortic arch is reasonable for acute dissection when the arch is aneurysmal or there is extensive aortic arch destruction and leakage.

3. Replacement of the entire aortic arch is reasonable for aneurysms of the entire arch, for chronic dissection when the arch is enlarged, and for distal arch aneurysms that also involve the proximal descending thoracic aorta, usually with the elephant trunk procedure.

4. For patients with low operative risk in whom an isolated degenerative or atherosclerotic aneurysm of the aortic arch is present, operative treatment is reasonable for **asymptomatic** patients when the diameter of the **arch exceeds 5.5 cm**.

5. For patients with isolated aortic arch aneurysms less than 4.0 cm in diameter, it is reasonable to reimage using computed tomographic imaging or magnetic resonance imaging, at 12-month intervals, to detect enlargement of the aneurysm.

6. For patients with isolated aortic arch aneurysms 4.0 cm or greater in diameter, it is reasonable to reimage using computed tomographic imaging or magnetic resonance imaging, at 6-month intervals, to detect enlargement of the aneurysm.

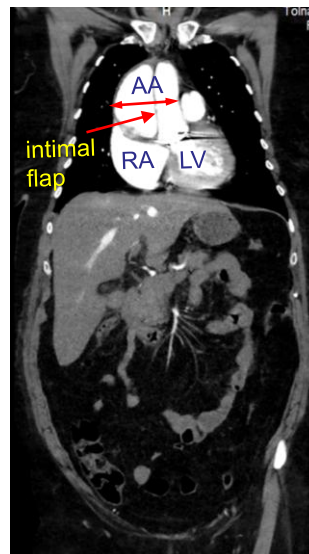
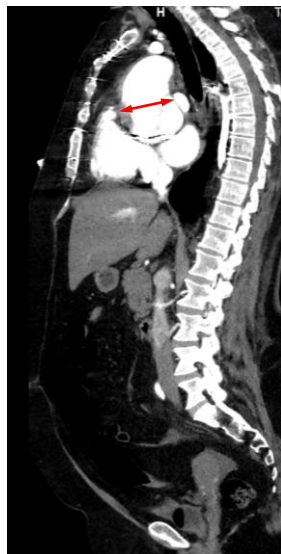


### Recommendations for Descending Thoracic Aorta and Thoracoabdominal Aortic Aneurysms

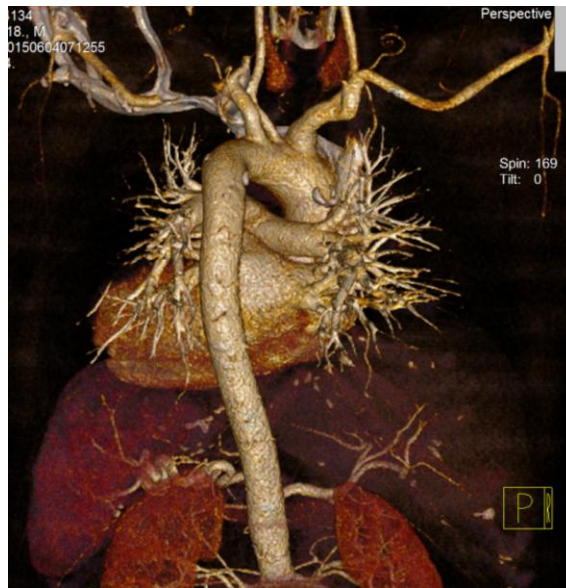
1. For patients with chronic dissection, particularly if associated with a connective tissue disorder, but without significant comorbid disease, and a descending thoracic aortic diameter **exceeding 5.5 cm**, open repair is recommended.
2. For patients with degenerative or traumatic aneurysms of the descending thoracic aorta exceeding 5.5 cm, saccular aneurysms, or postoperative pseudoaneurysms, endovascular stent grafting should be strongly considered when feasible.
3. For patients with **thoracoabdominal** aneurysms, in whom endovascular stent graft options are limited and surgical morbidity is elevated, elective surgery is recommended if the aortic diameter **exceeds 6.0 cm**, or less if a connective tissue disorder such as Marfan or Loeys- Dietz syndrome is present.
4. For patients with thoracoabdominal aneurysms and with end-organ ischemia or significant stenosis from atherosclerotic visceral artery disease, an additional revascularization procedure is recommended.

## Chronic dissection on ascending aorta

---

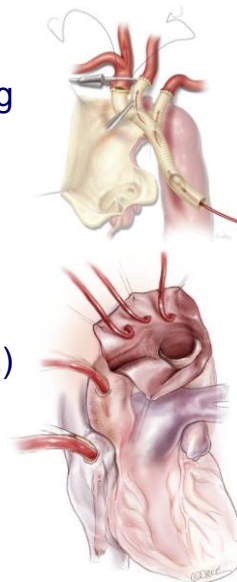

## Ascending aorta aneurysm, CTA 3D



## Hypothermia, cerebral protection

- Extracorporeal circulation (heparinization)
- Decreasing metabolic demand by cooling (profound  $\leq 14^{\circ}\text{C}$ , deep  $\leq 20^{\circ}\text{C}$ , moderate  $\leq 28^{\circ}\text{C}$ , mild  $\leq 34^{\circ}\text{C}$  hypothermia)
- Circulatory arrest (at  $20^{\circ}\text{C}$ : 30-40 min)
- Selective brain perfusion (ante, retro)
- Selective visceral perfusion (thoracoabd.)
- Ice around the head
- Deep anaesthesia, barbiturate
- Room temperature set at  $20^{\circ}\text{C}$

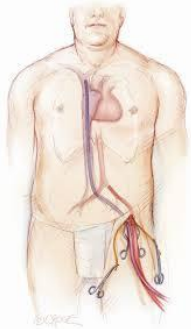


# Cannulation techniques

---

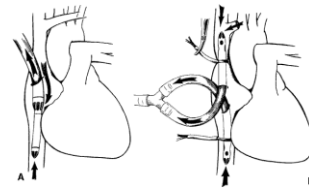
## Arterial access:

- Ascending aorta
- Anonymus artery
- Proximal arch
- Axillary artery
- Femoral artery
- Carotid artery
- Vascular graft
- Lig. arteriosum
- Any other...



## Venous access:

- Right atrium
  - two stage
  - bicaval
- Femoral vein



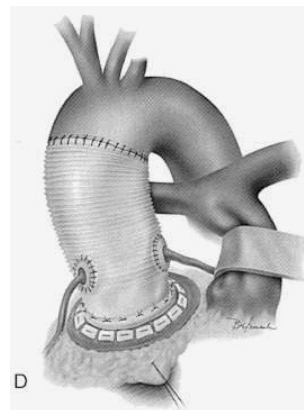
# Bentall-procedure (valve+graft)

---

*Conduit with valve*

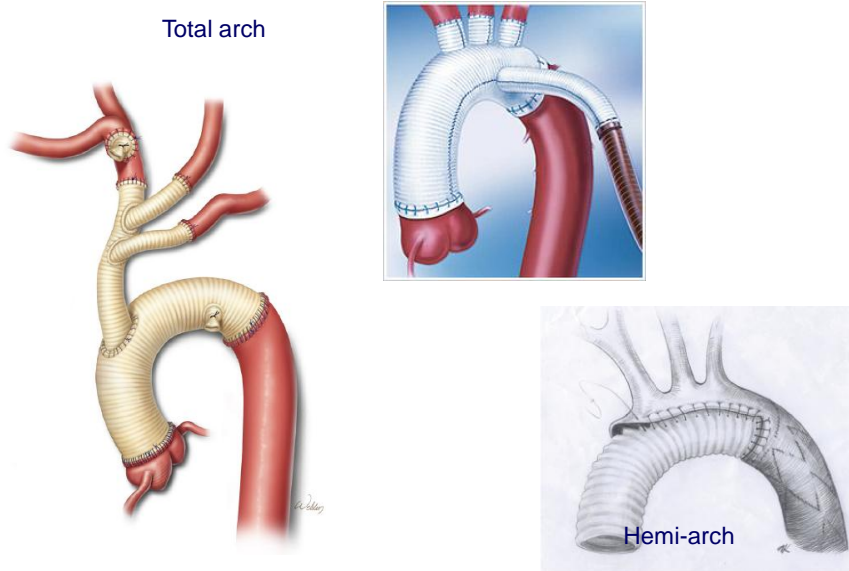


*Valvular conduit with CABG in situ*



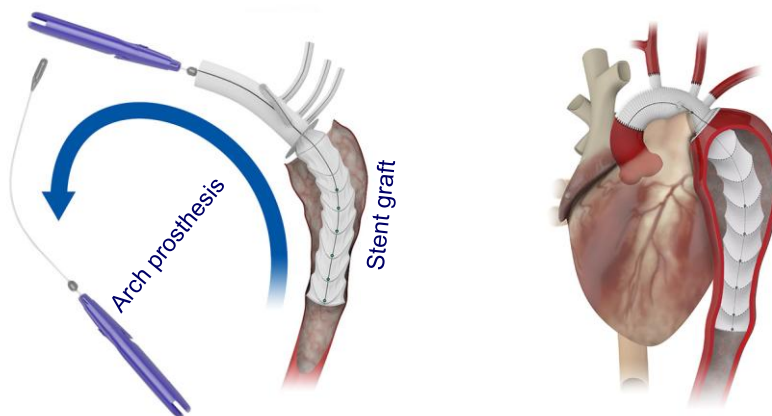
## Prostheses – aortic arch

---

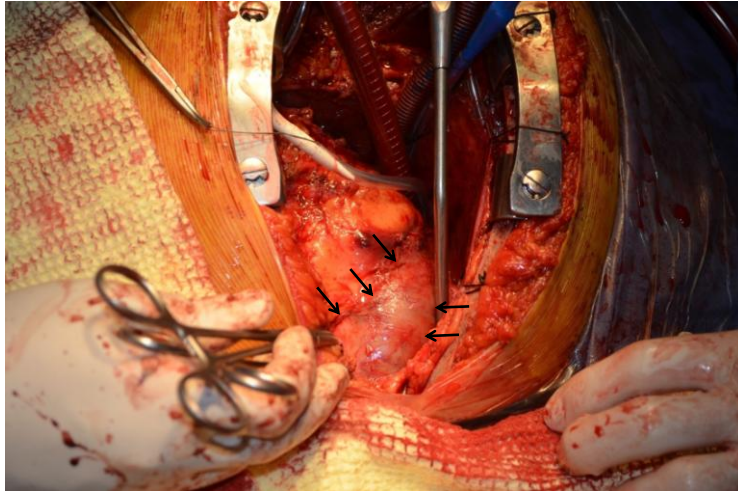


## Prostheses – frozen elephant trunk

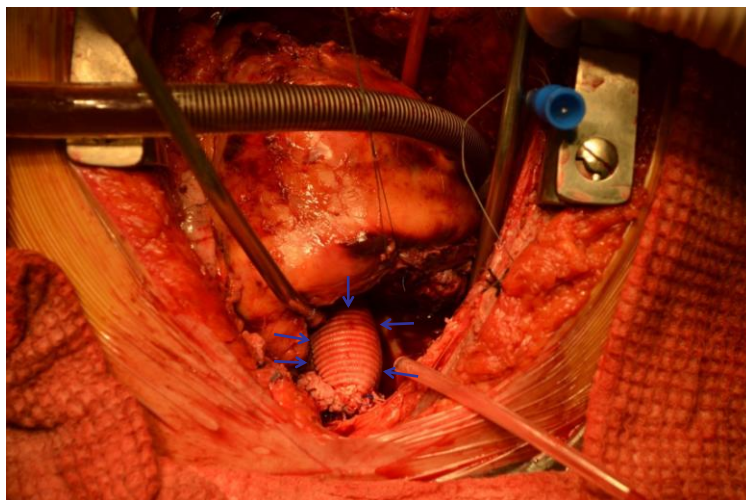
---



## Chronic ascending dissection

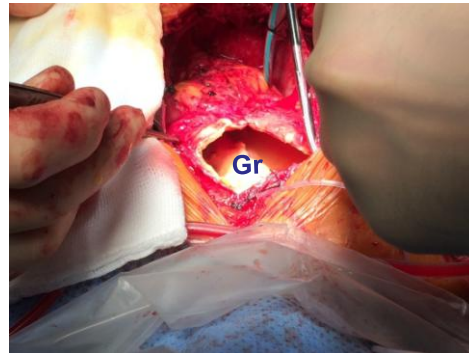
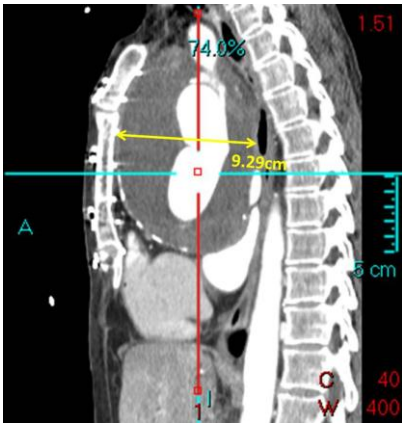


## Ascending conduit in situ



## Giant ascending perigraft seroma

---



**Thank you for your attention !**

---

