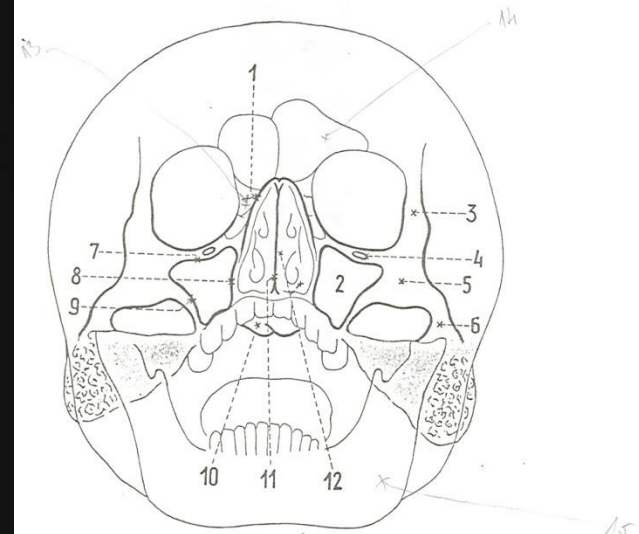
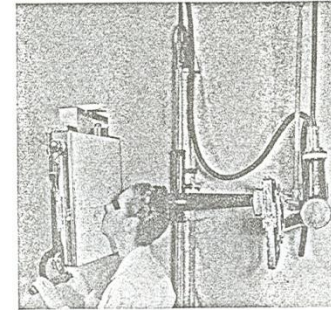
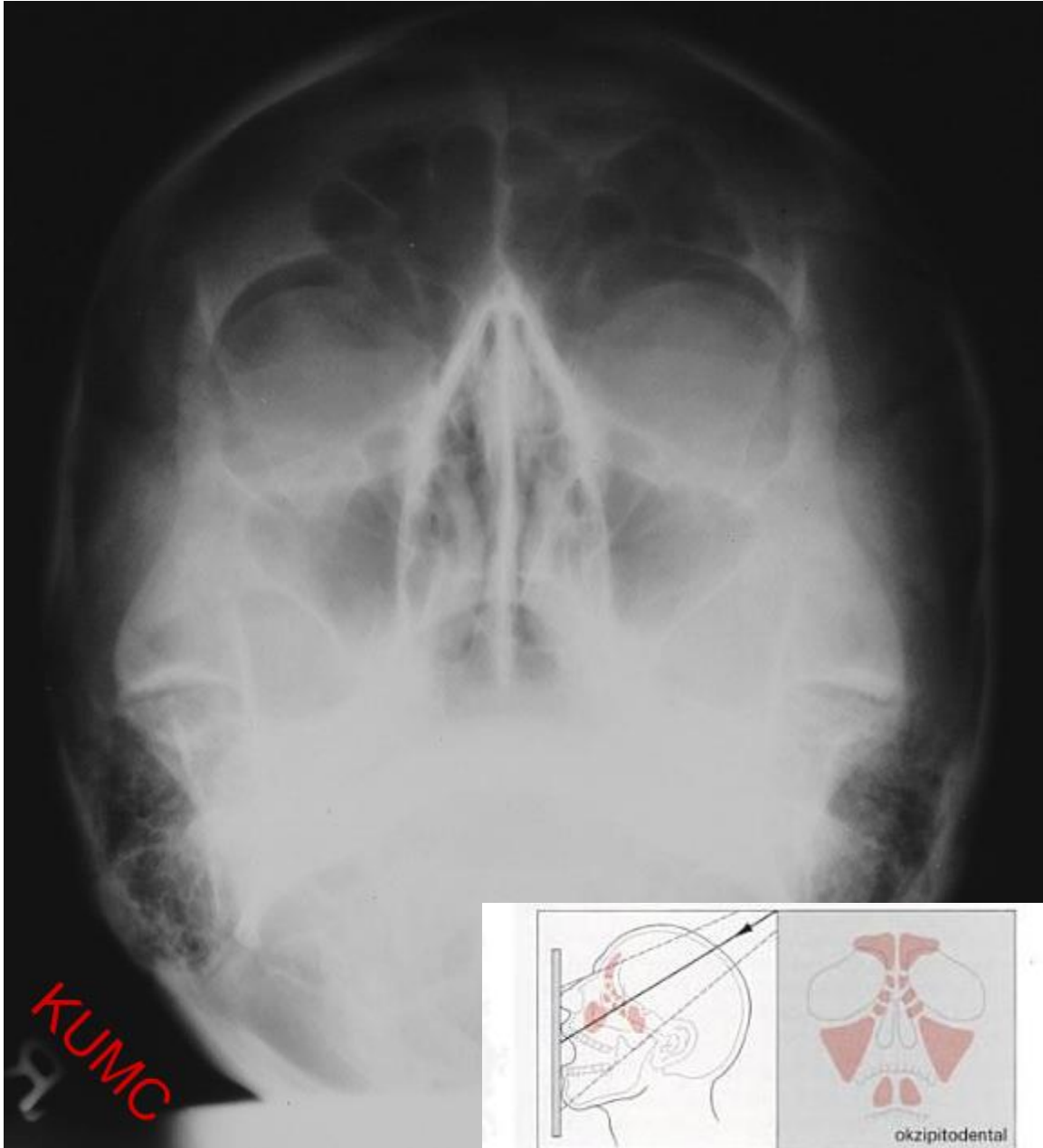
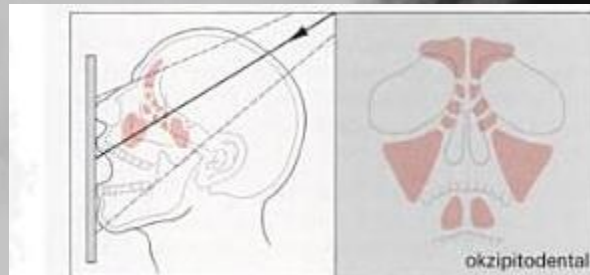


# Waters-felvétel (occipito-dentális felvétel)



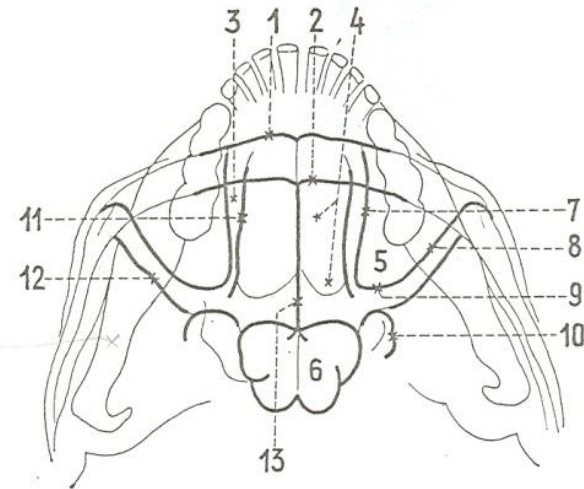
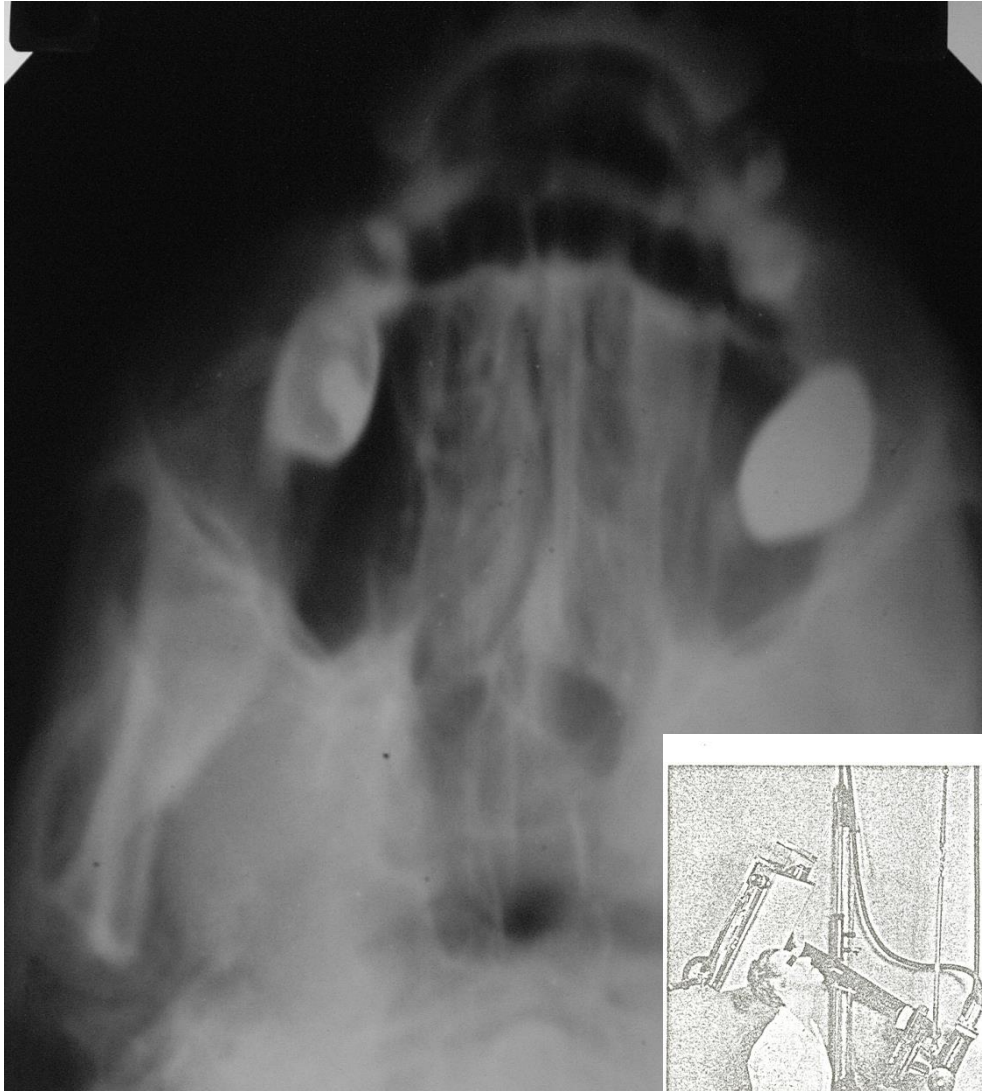
1. Nasal bone
2. Maxillary sinus
3. Frontal process of zygomatic bone
4. Infraorbital canal
5. Zygomatic bone
6. Zygomatic arch
7. Superior wall of the maxillary sinus
8. Nasal (medial) wall of the maxillary sinus
9. Lateral wall of the maxillary sinus
10. Sphenoid sinus
11. Nasal septum
12. Nasal cavity
- A3 Anterior ethmoidal cells
- A4 Frontal sinus
- A5 Mandibula



KUMC



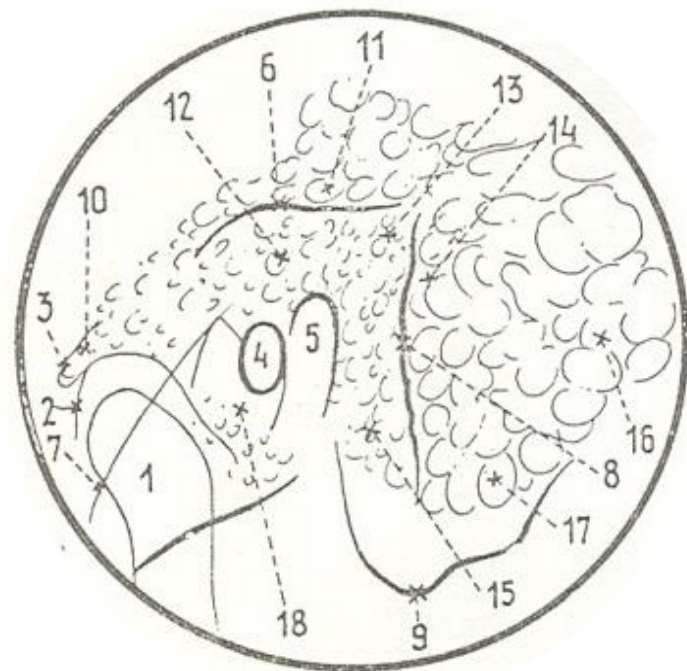
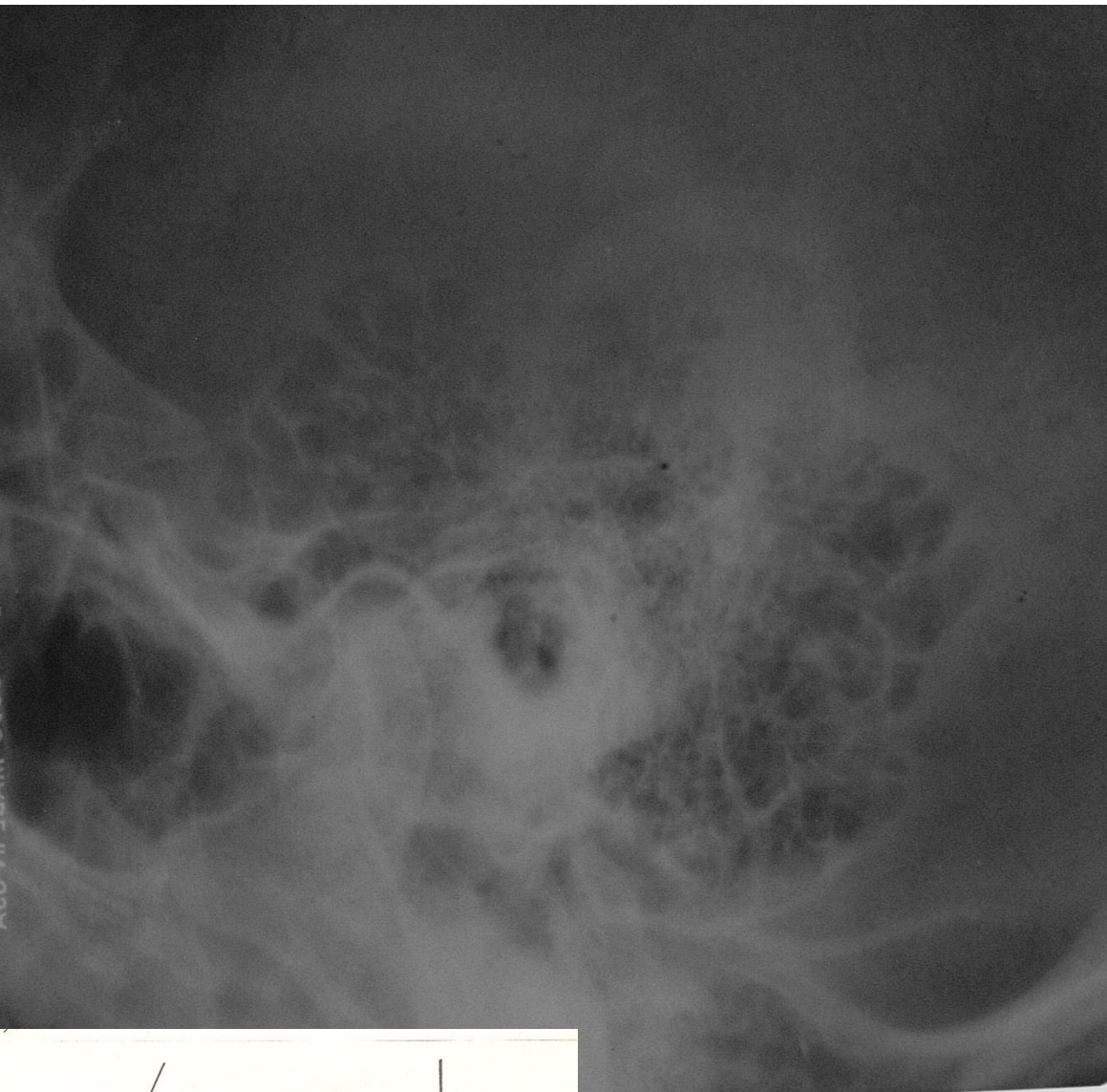
# Welin felvétel ( submentális-vertex felvétel, „axiális”)



1. Anterior wall of the frontal sinus
2. Posterior wall of the frontal sinus
3. Anterior ethmoid cells
4. Nasal cavity and posterior ethmoid cells
5. Maxillary sinus
6. Sphenoid sinus
7. Medial wall of the maxillary sinus
8. Lateral wall of the maxillary sinus
9. Posterior wall of the maxillary sinus
10. Pterigoid process
11. Medial wall of orbit
12. Lateral wall of orbit
13. Nasal septum
14. Mandibula



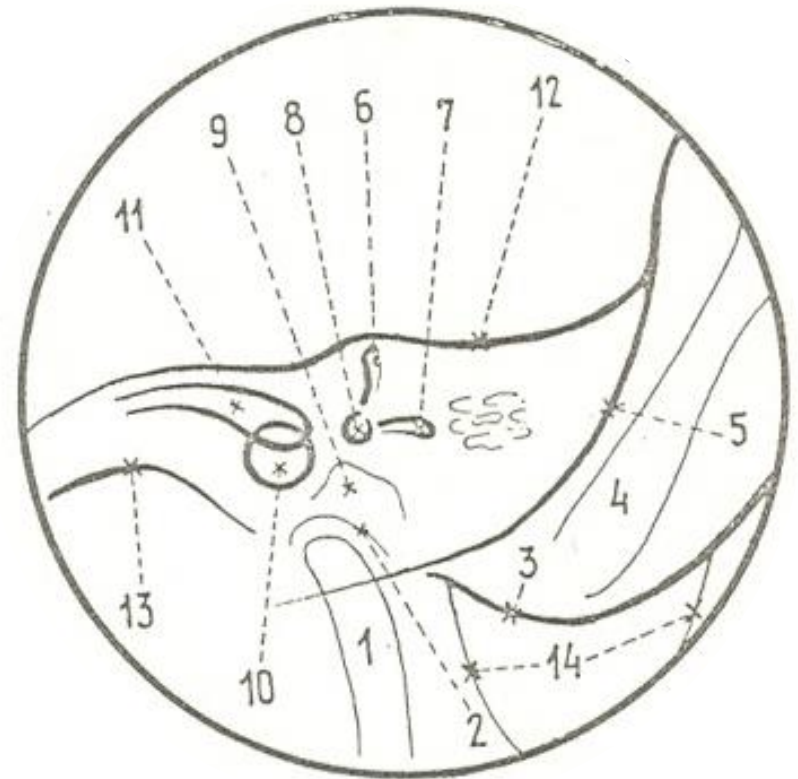
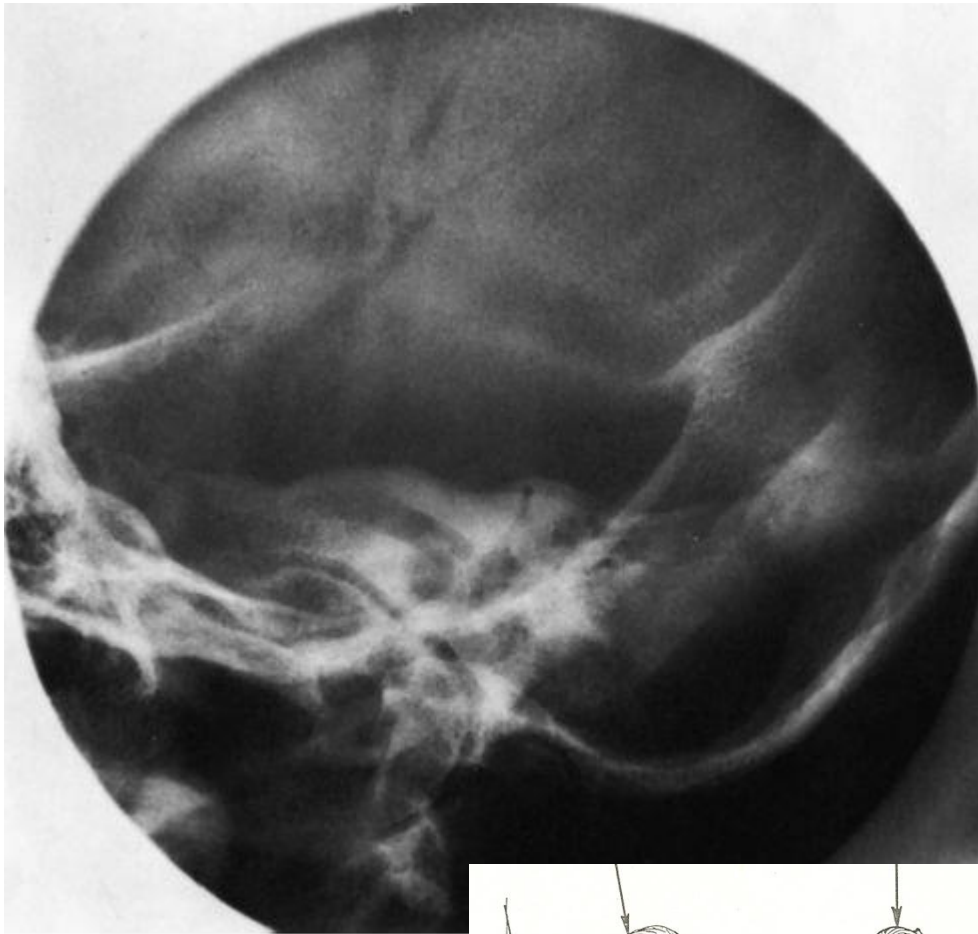
# Schüller felvétel



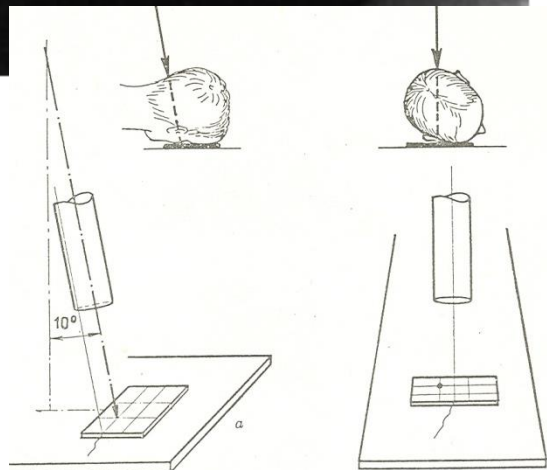
1. Head of mandible
  2. Temporomandibular joint
  3. Root of zygomatic bone
  4. External auditory canal + cavity of the middle ear + internal auditory canal
  5. Labyrinth
  6. Floor of middle cranial fossa
  7. Superior petrous margin
  8. Anterior sinus plate and posterior margin of petrous bone
  9. Mastoid tip
  10. Zygomatic cells
  11. Squamous cells
  12. Periantral cells
  13. Citelli's angle
  14. Cells superficial to the sinus
- } Mastoid air cells



# Stenvers felvétel



1. Head of mandible
2. Temporomandibular joint
3. Posterior cranial fossa
4. Sinus sigmoideus
5. Crista sagittalis
6. Superior semicircular canal
7. Lateral semicircular canal
8. Vestibule
9. Area of jugular foramen
10. Basal turn of cochlea
11. Internal auditory canal
12. Superior petrous margin
14. Processus mastoideus
13. Zygomatic arch



# Orrcsont felvétel

