



# Kardiológiai képző diagnosztikai eljárások: Szív CT és MR

Dr. Gaszner Balázs med.habil.

Egyetemi docens

PTE, KK, Szívgyógyászati Klinika

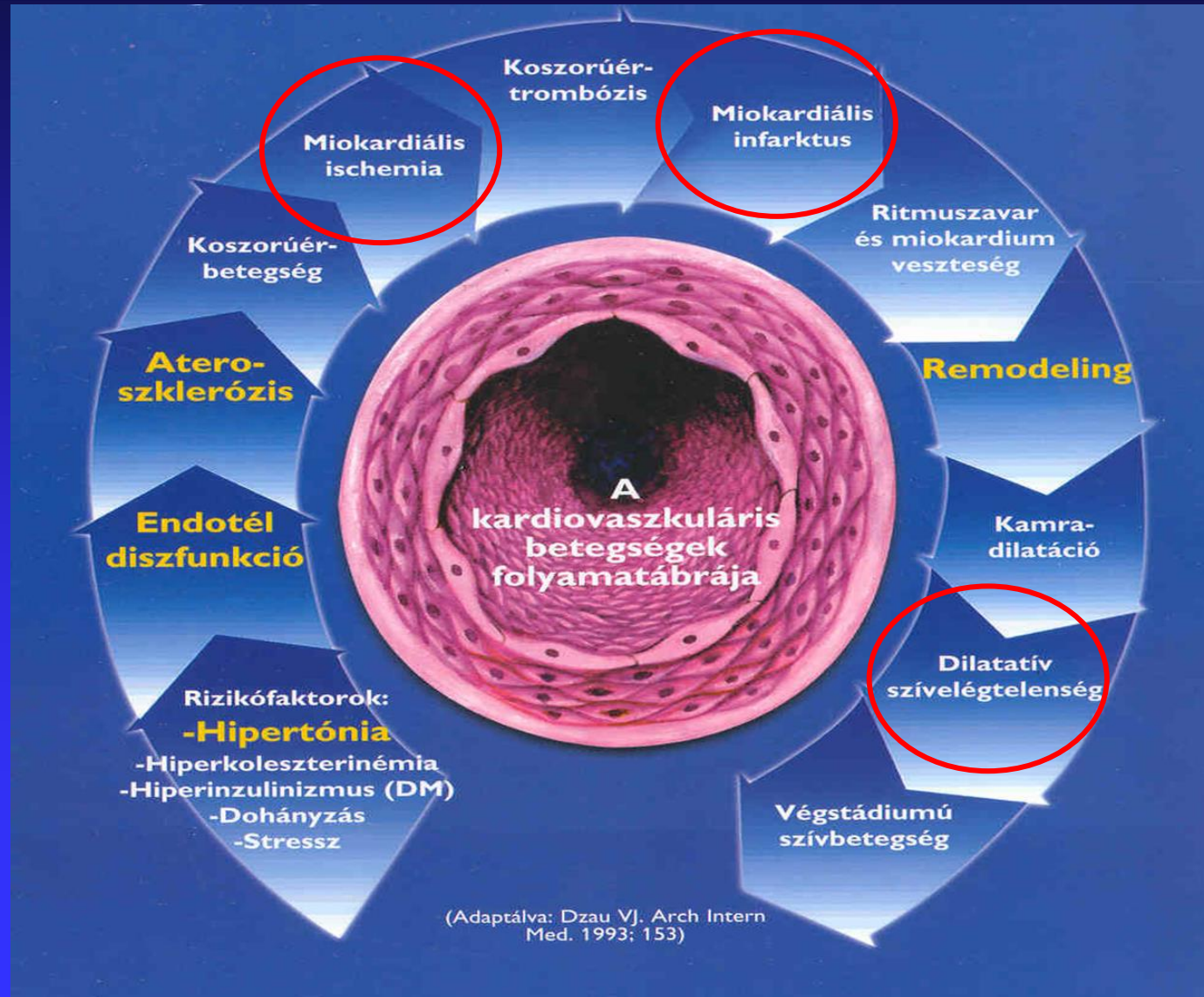
2026.



# WHO előrejelzése a vezető halálokokról

2016		2030
Ischaemiás szívbetegségek	1.	Ischaemiás szívbetegségek
Cerebrovascularis betegségek	2.	Cerebrovascularis betegségek
Alsó légúti infekciók	3.	COPD
Diarrhoea betegségek	4.	Alsó légúti infekciók
Perinatalis rendellenességek	5.	Tüdőrák
COPD	6.	Közlekedési baleset
Tuberculosis	7.	Tuberculosis
Kanyaró	8.	Gyomorrák
Közlekedési baleset	9.	HIV
Tüdőrák	10.	Öngyilkosság

# Kardiovaszkuláris betegségek folyamatábrája

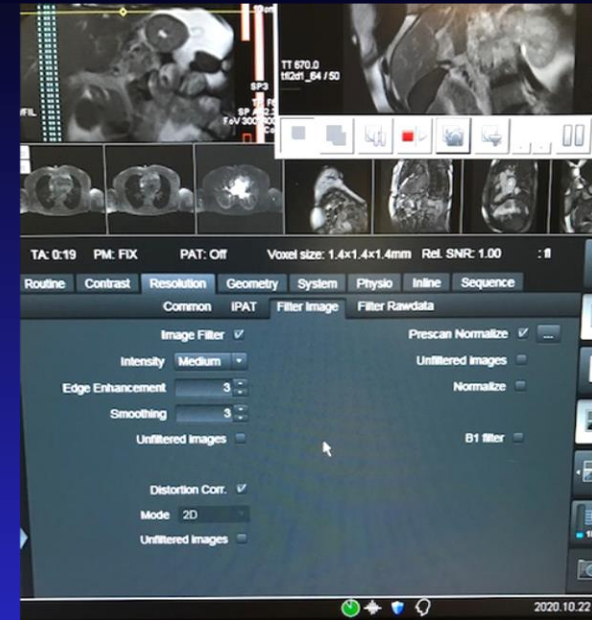

MRI szerepe



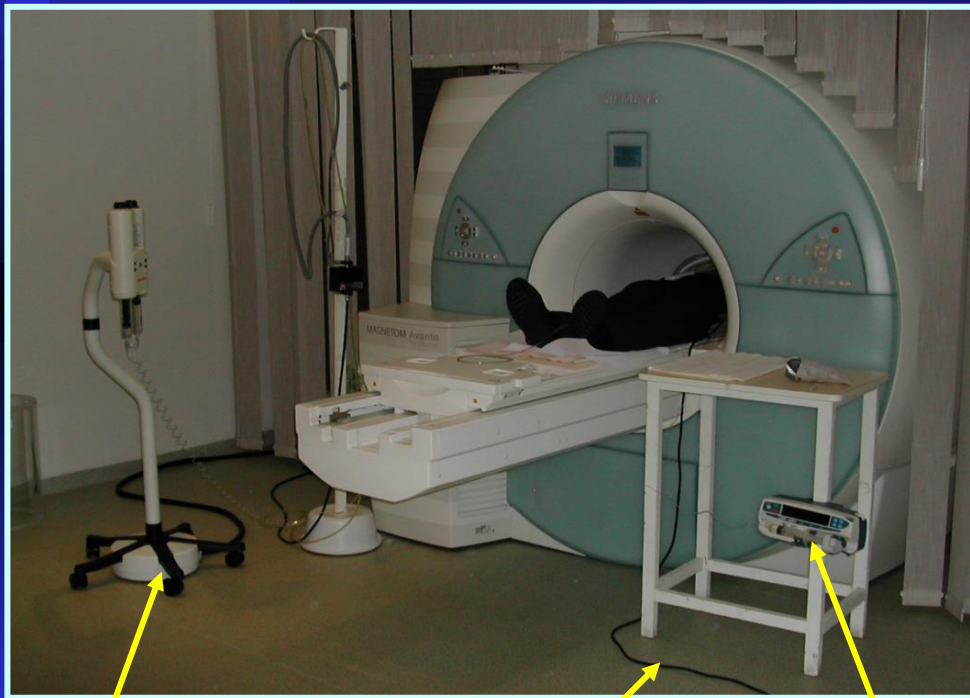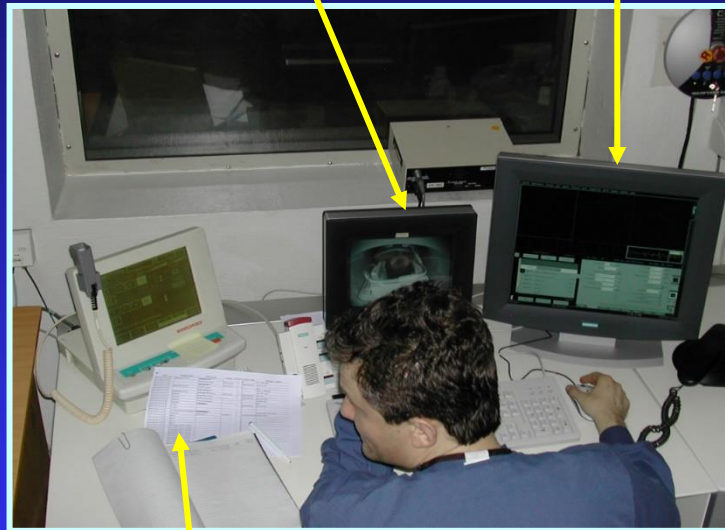
# Kardiovaszkuláris MRI

## 3 Nobel díj



Vizuális és verbális kommunikáció

EKG & SpO2



Kontrasztanyag injektor

Nem Invazív Vérnyomás

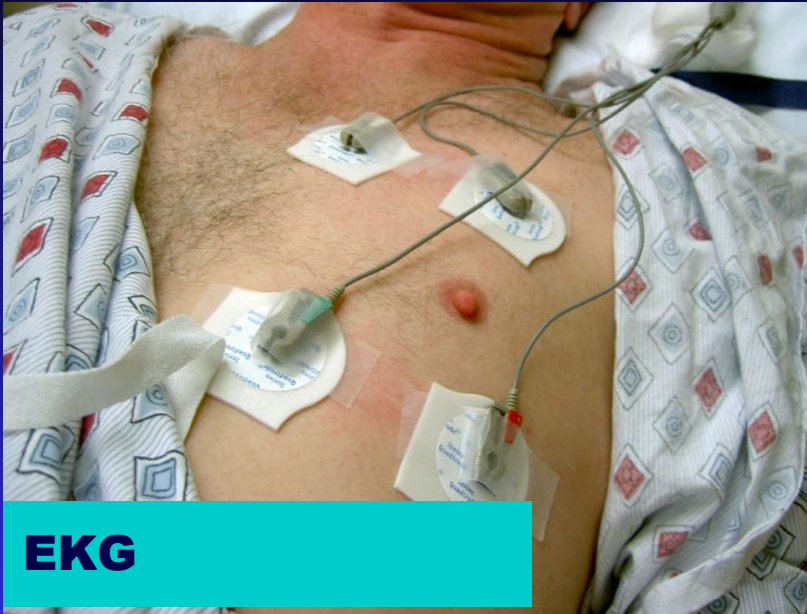Stresszor pumpa

Kontraszt anyag injekció

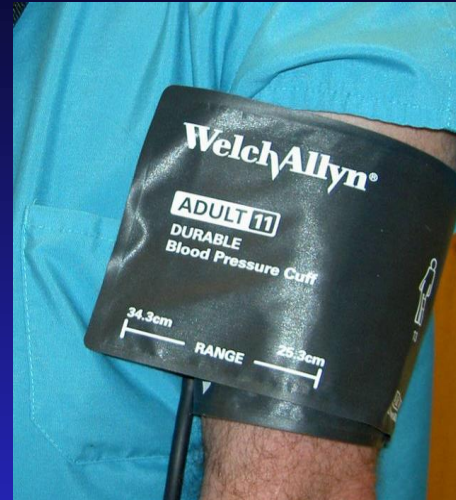



# Kardiovaszkuláris MRI: biztonság



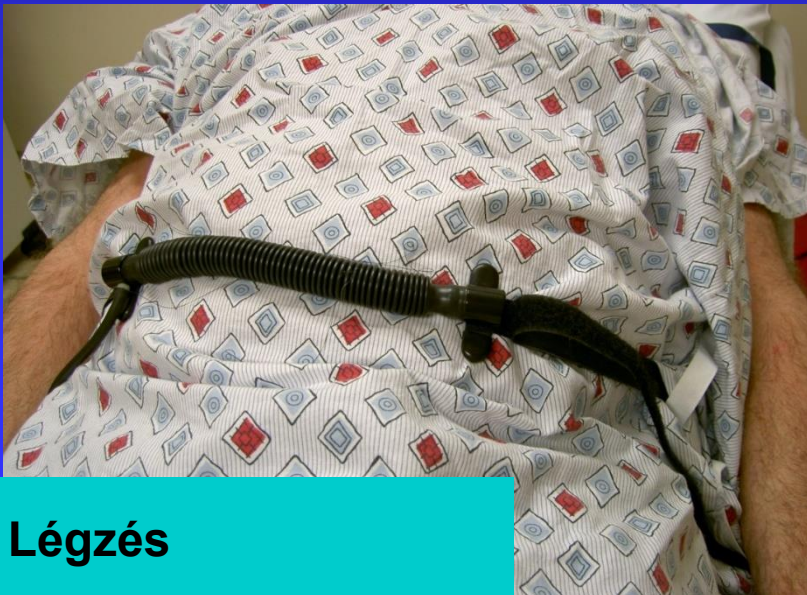**EKG**



**Vérnyomás**



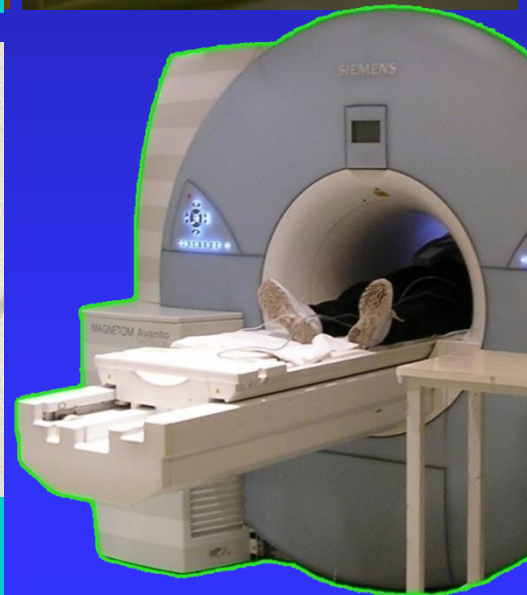
**SpO2**



**Légzés**



**Videó**

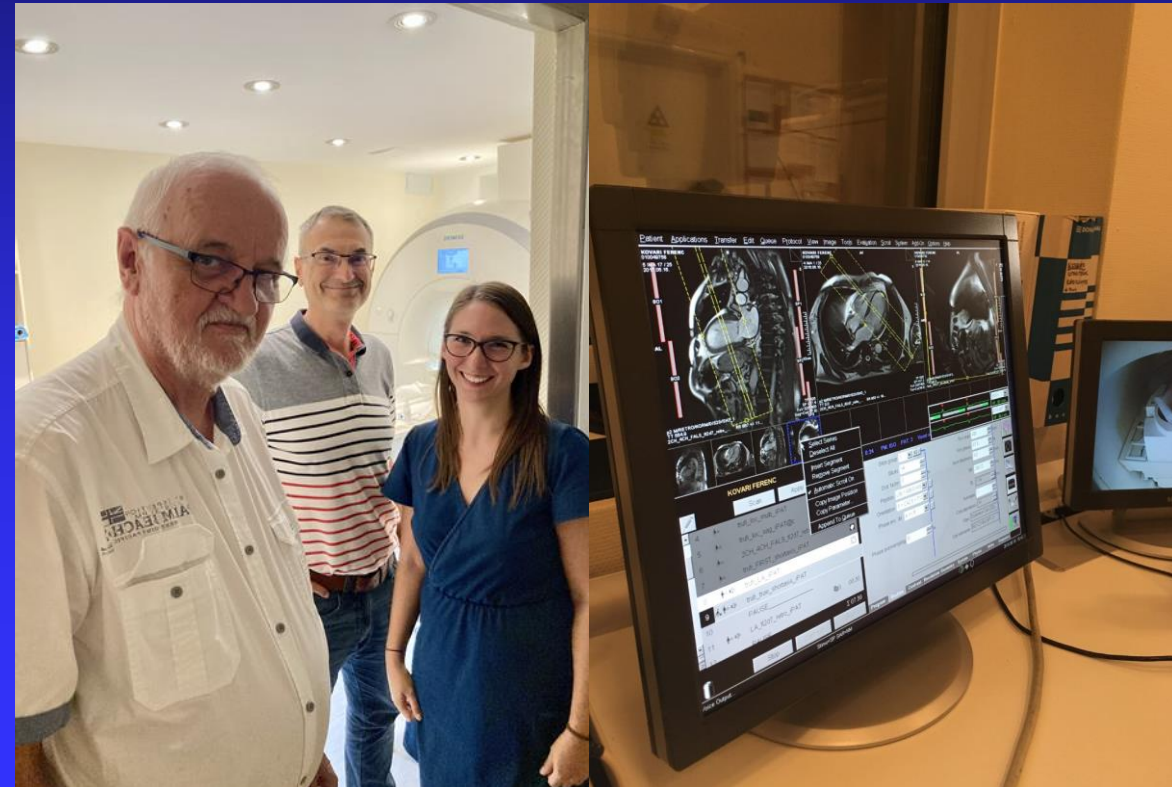




# Kardiovaszkuláris MRI

**Előnyei:** Fájdalom mentes (non-invasív)  
Pontos (felbontás)  
Nélkülözhetetlen információk  
Sugárzás mentesen

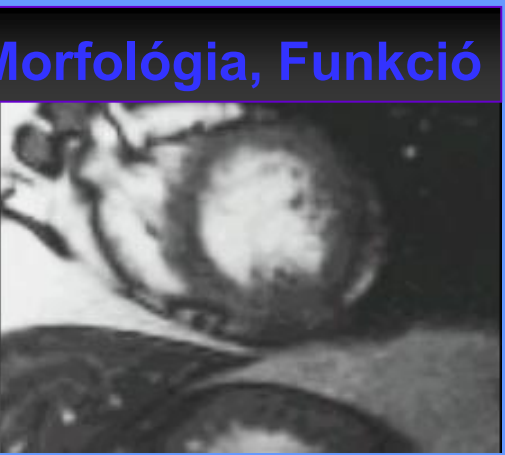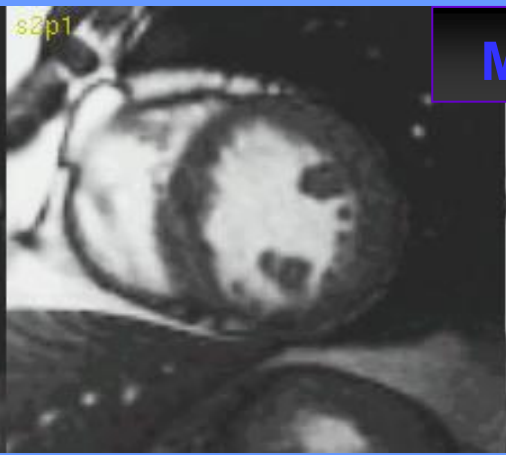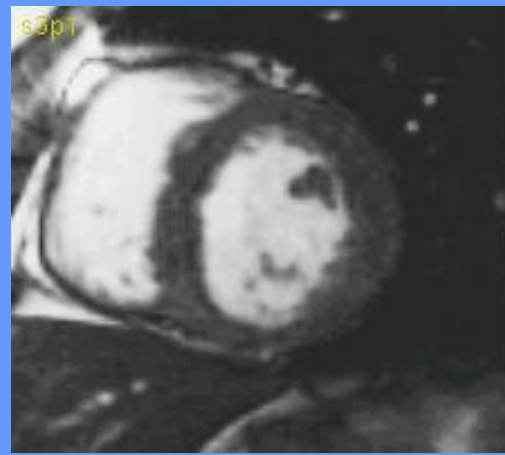**Hátrányai:** Bezártság, klausztrofóbia  
Drága, indikáció szükséges  
Szakember igényes



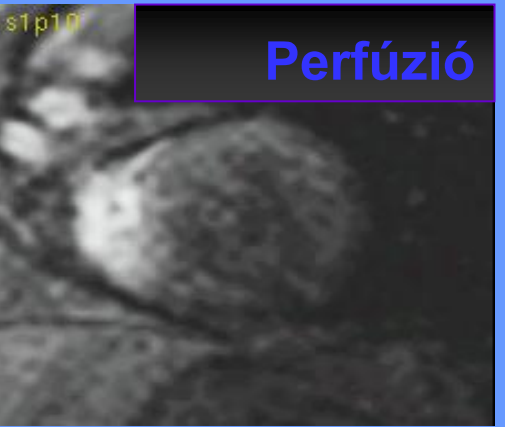
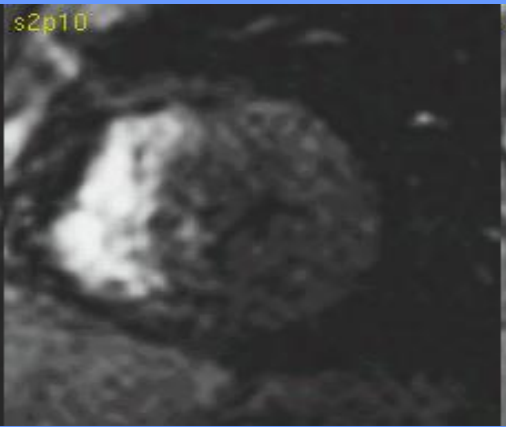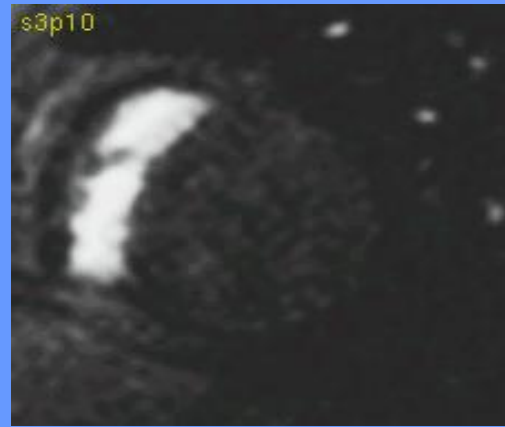


# Szív MRI technikák

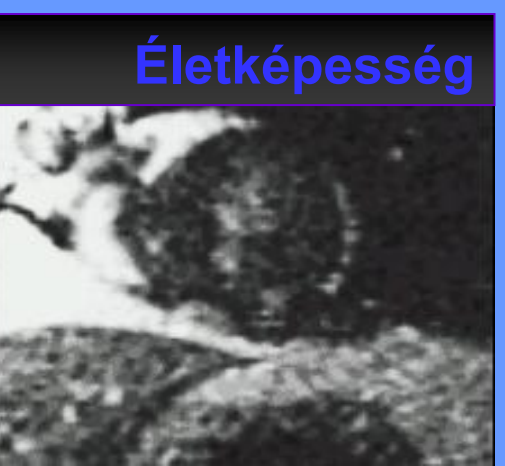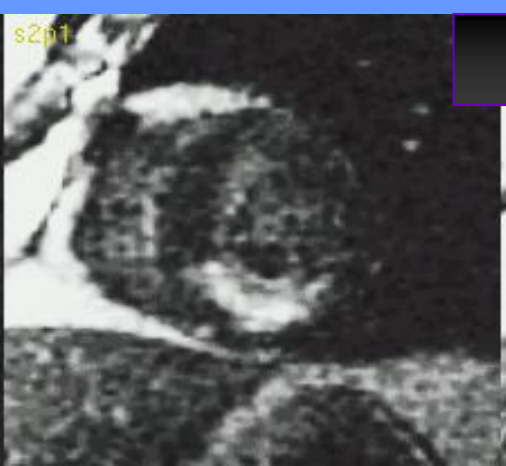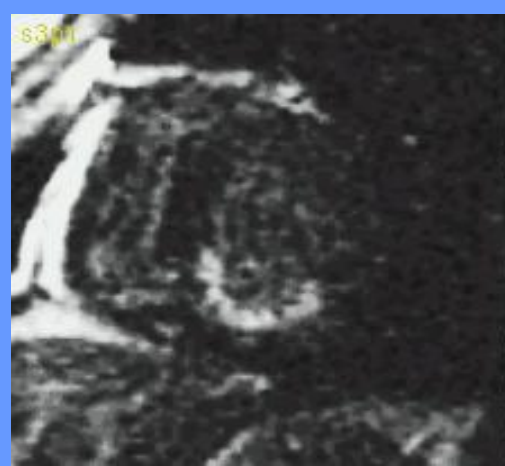- Morfológia
- Funkció
- Szöveti tipizálás (T1, T2, ECV, LGE)
- Perfúzió (stressz teszt, ischaemia)
- Áramlásmérés (billentyűk, vitiumok)
- Angiographia (aortographia, coronarographia)



**Morfológia, Funkció**



**Perfúzió**



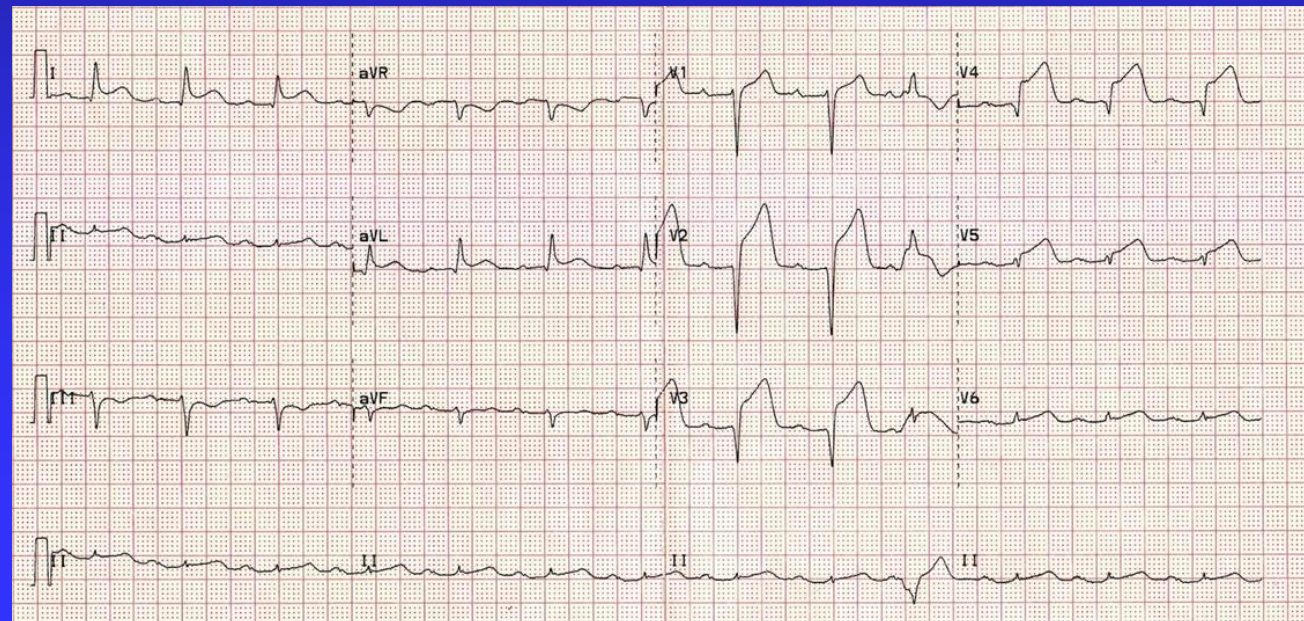
**Életképesség**



# Esetismertetés 1.

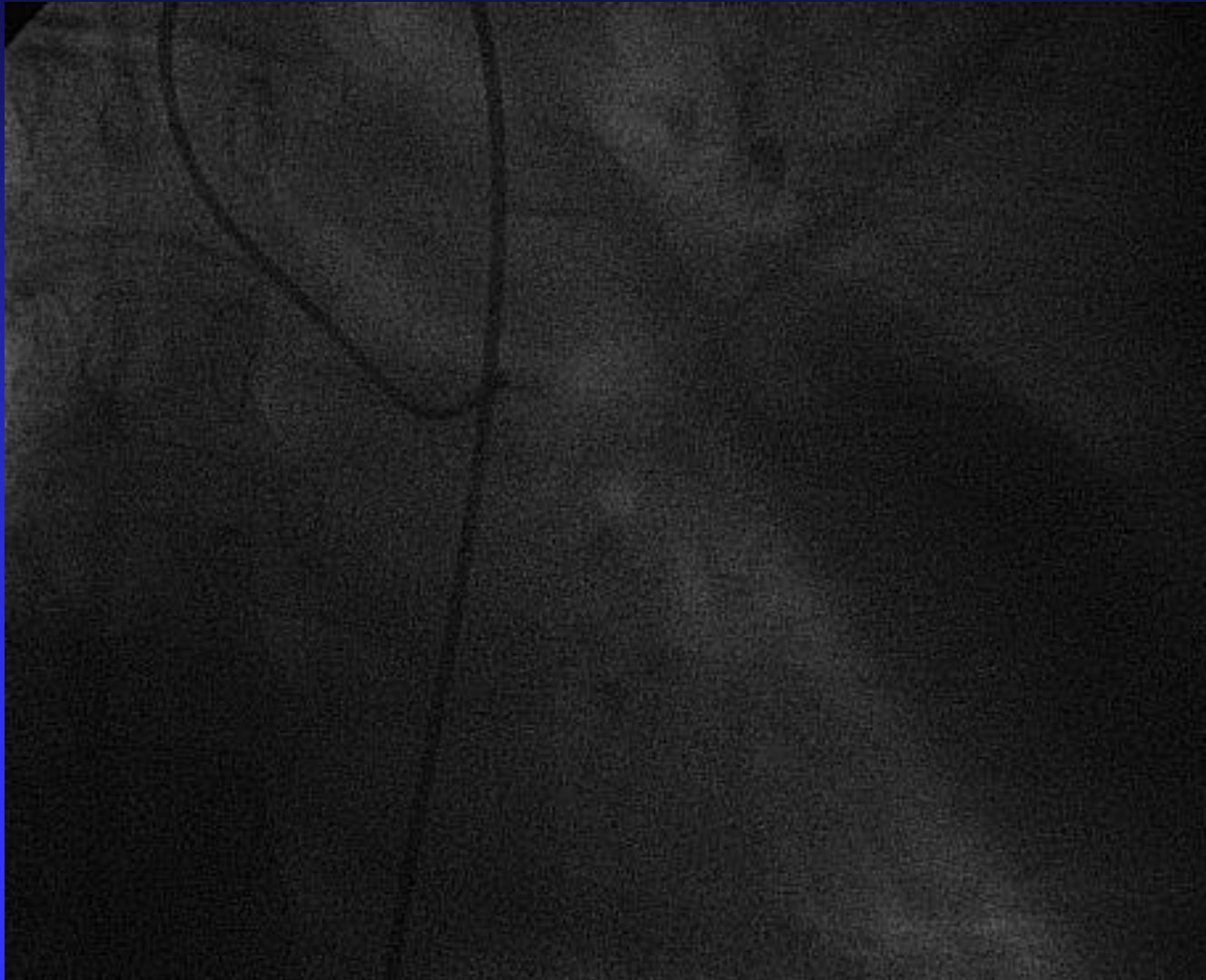- 71 éves obes nőbeteg (BMI: 31,3 kg/m<sup>2</sup>)
- Panasz: **4-5 órás** retrosternalis panasz, fél éve terhelésre fullad, típusos mellkasi panaszok, palpitáció érzés 2 hónapja, lábai nem duzzadnak, nycturia nincs, **kardiológiai előjegyzésben**
- Anamnézis: 15 éve ismert hypertonia  
8 éve T2DM  
3 éve hyperlipidémia

- Családi anamnézis cardiovascularis szempontból negatív
- Gyógyszerei: amlodipin, nebivolol, atorvastatin, metformin
- Igen magas CV rizikóstátus



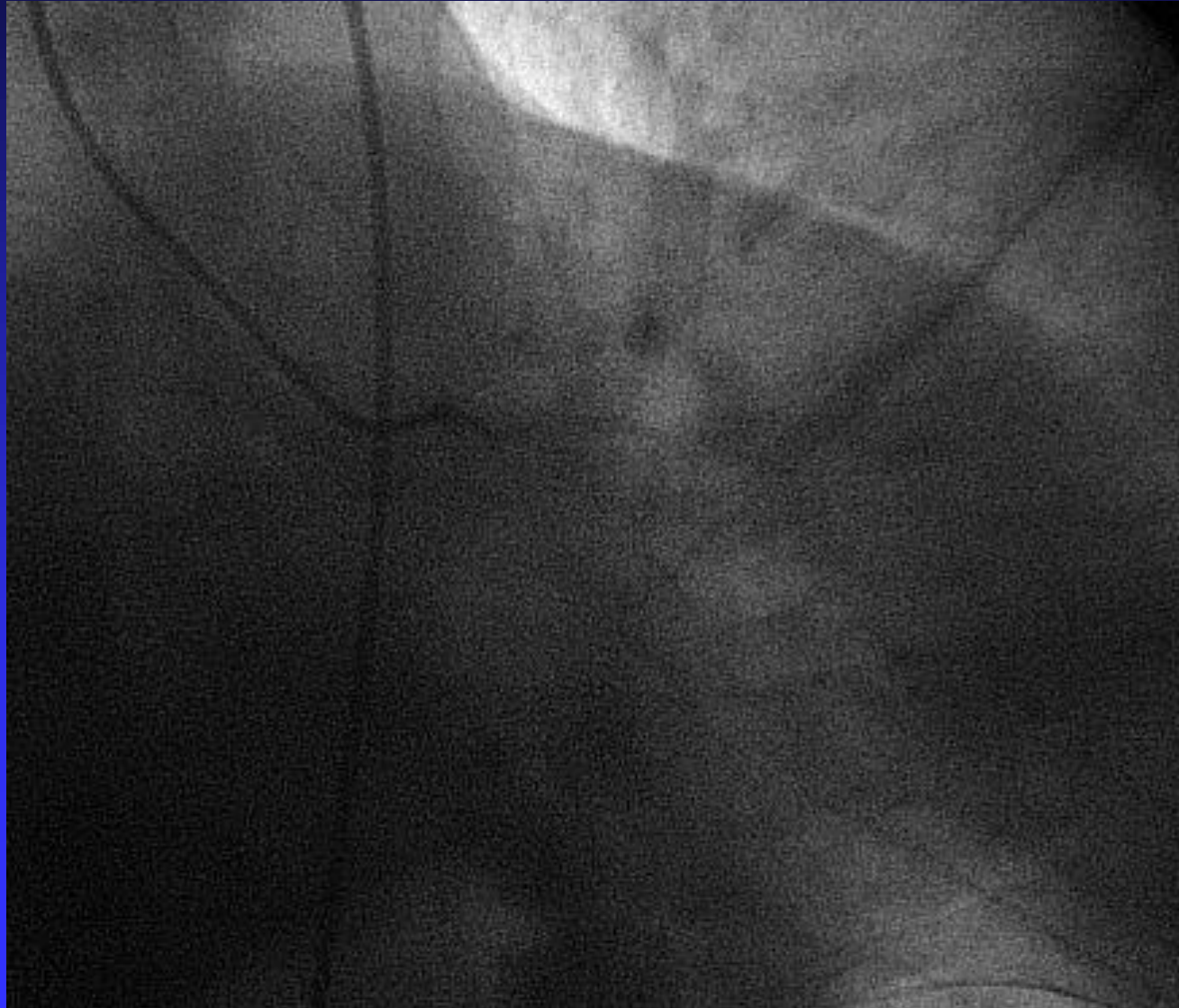


# Coronarographia



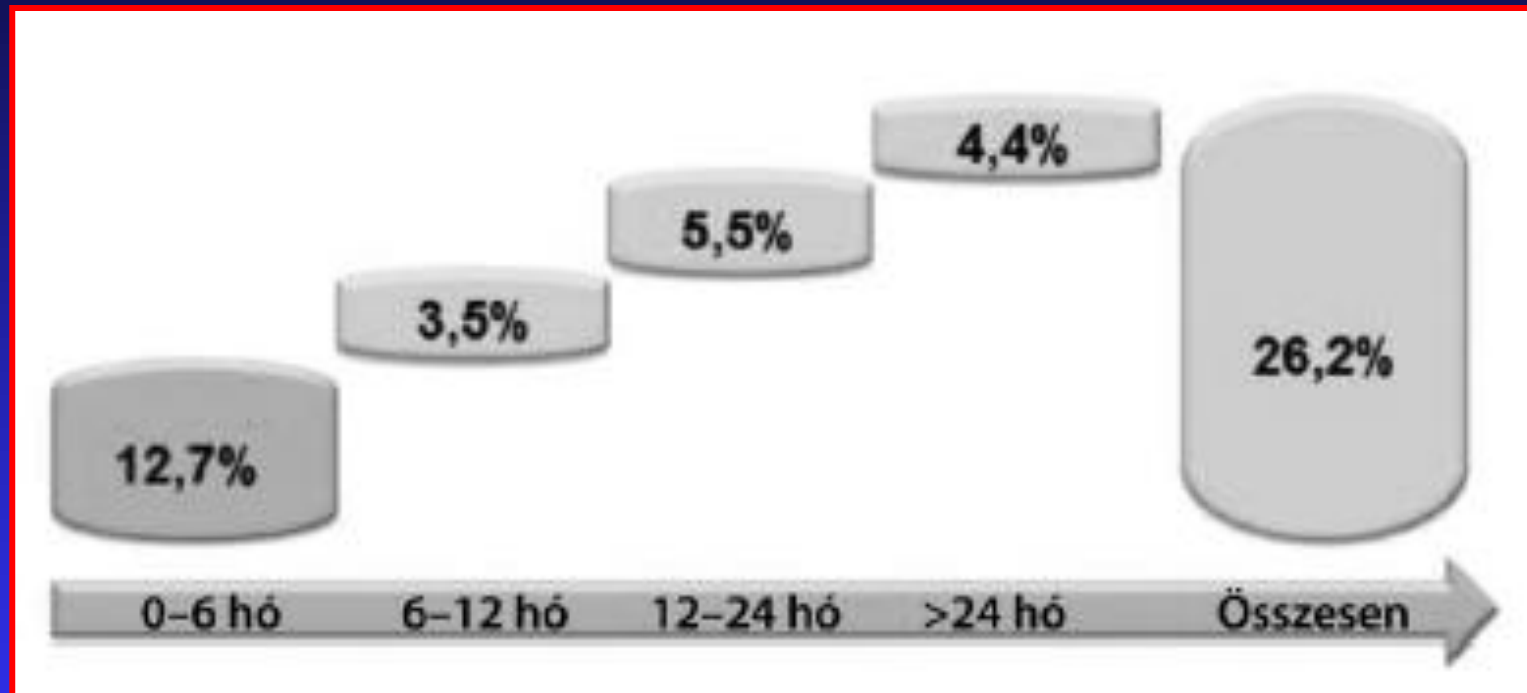


# Coronarographia - PCI





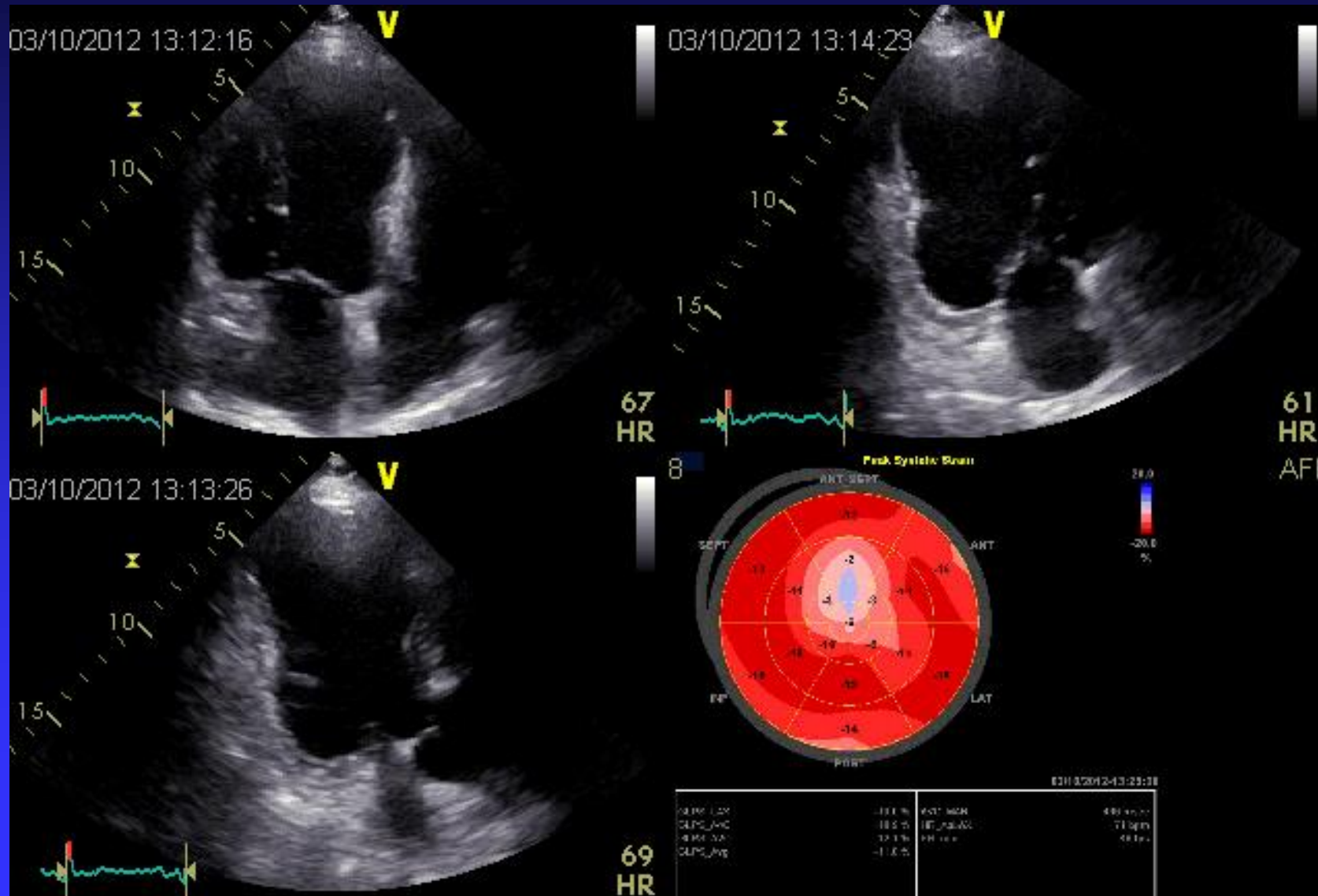
## Szívinfarktus utáni halálozás Mo-n



Nemzeti Szívinfarktus Regiszter (2024) ACS (STEMI, NSTEMI) 1 éves halálozása 23 %!!!

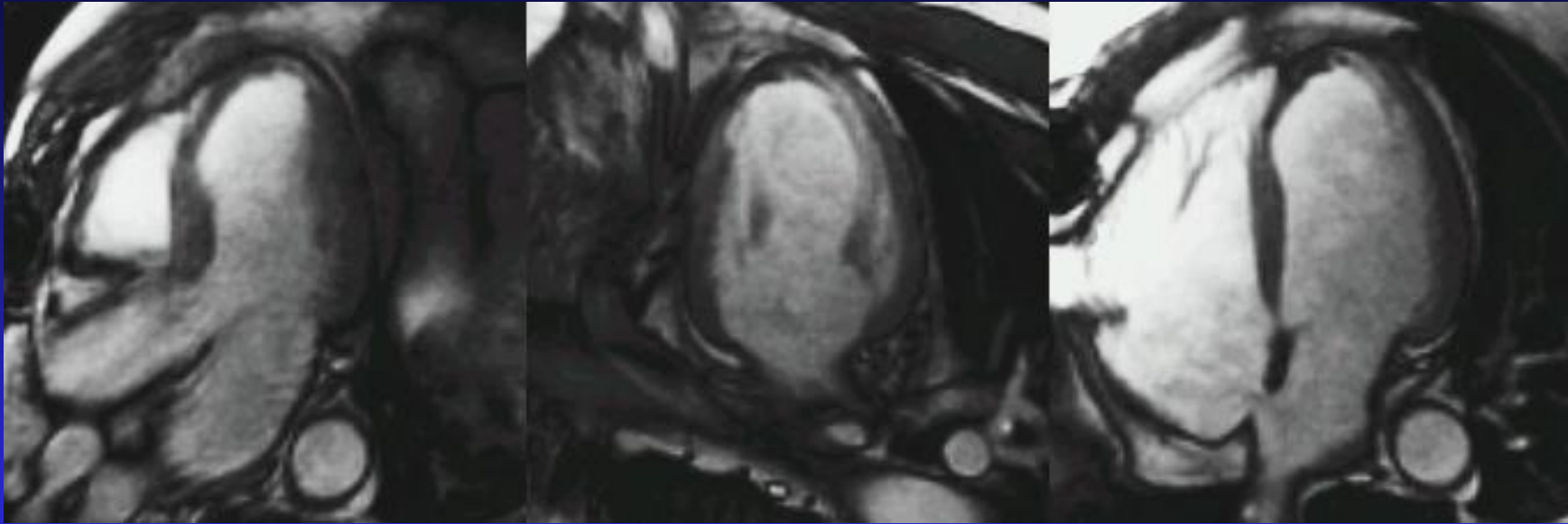


# Bal kamra csúcsi falmozgászavar



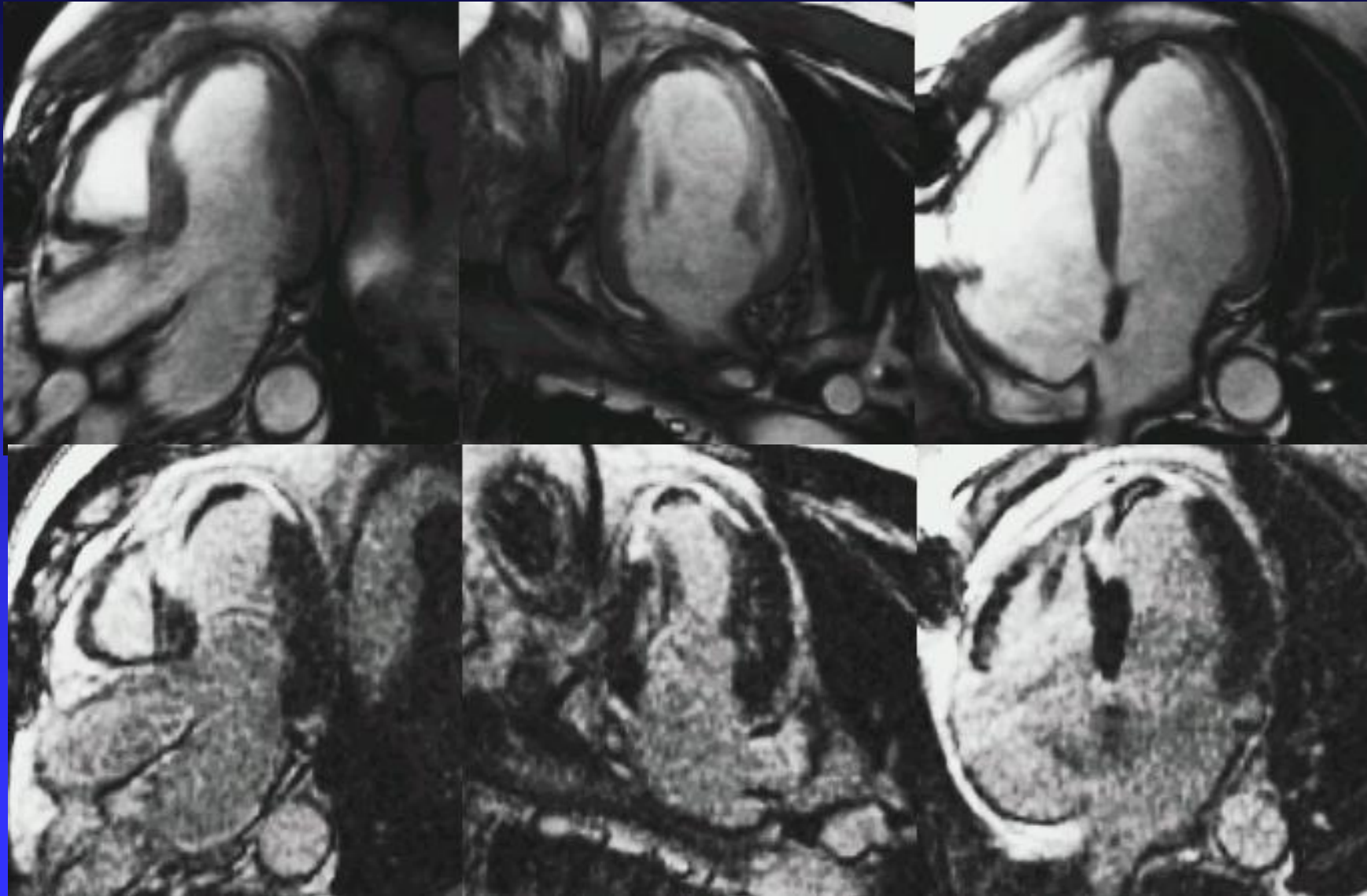


# Szívinfarktus és szövődményei



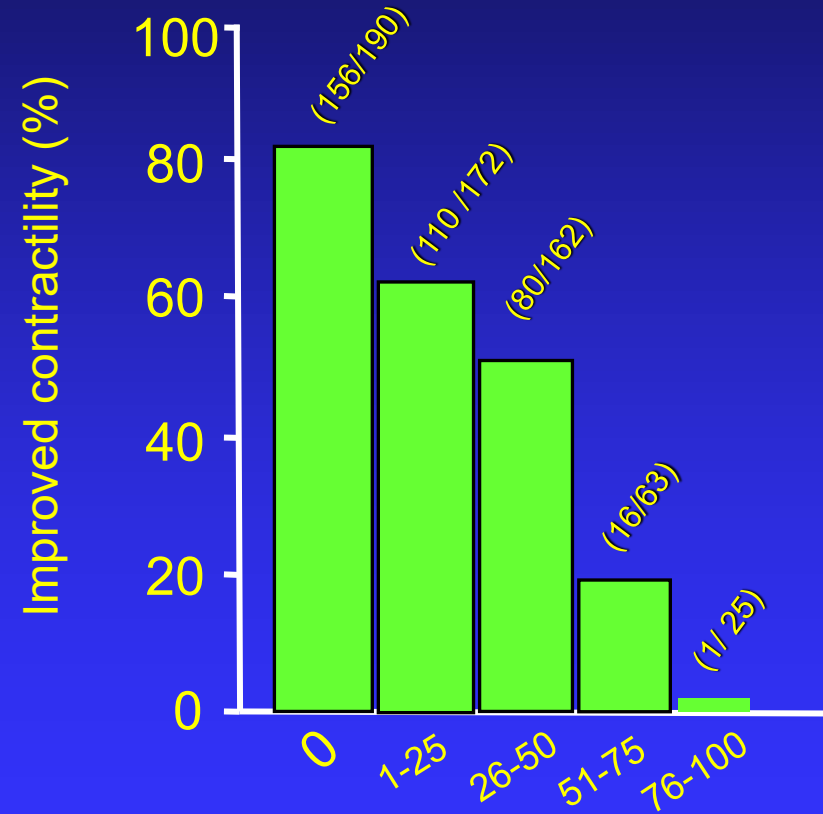
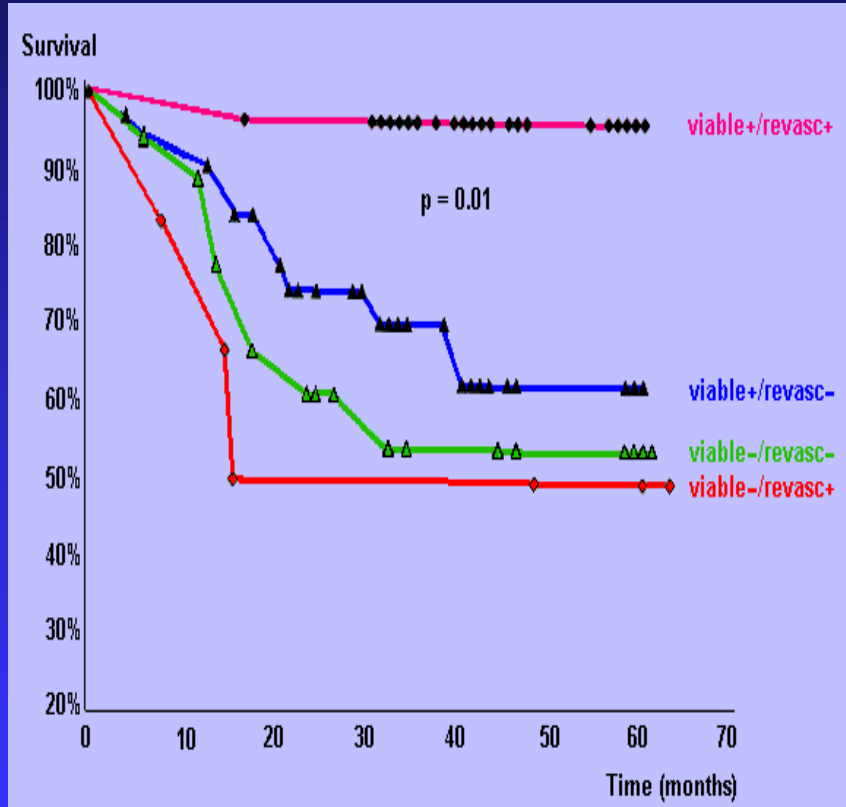


# Szívinfarktus és szövődményei: életképesség

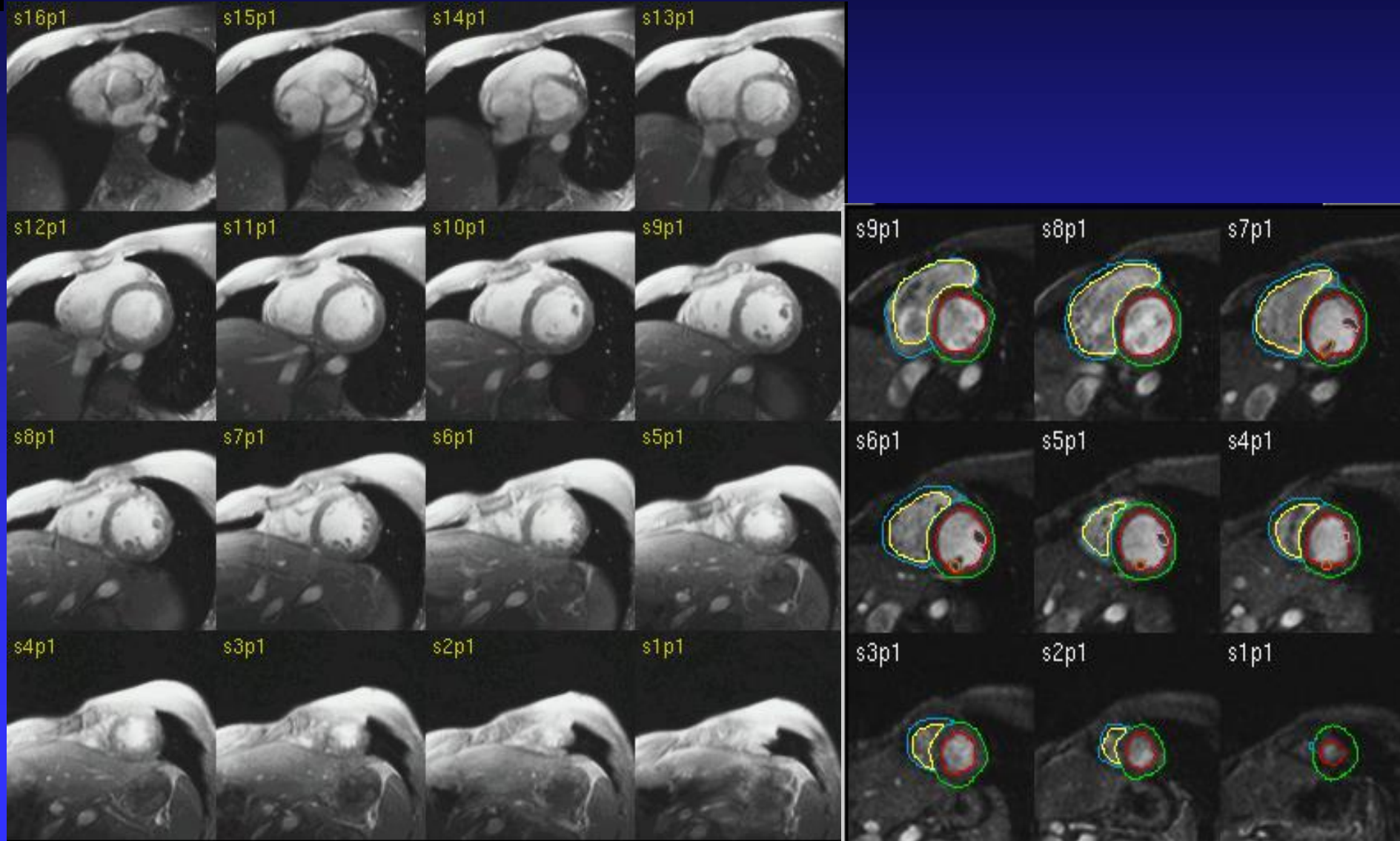




# Életképesség, de nem mindegy milyen mértékben

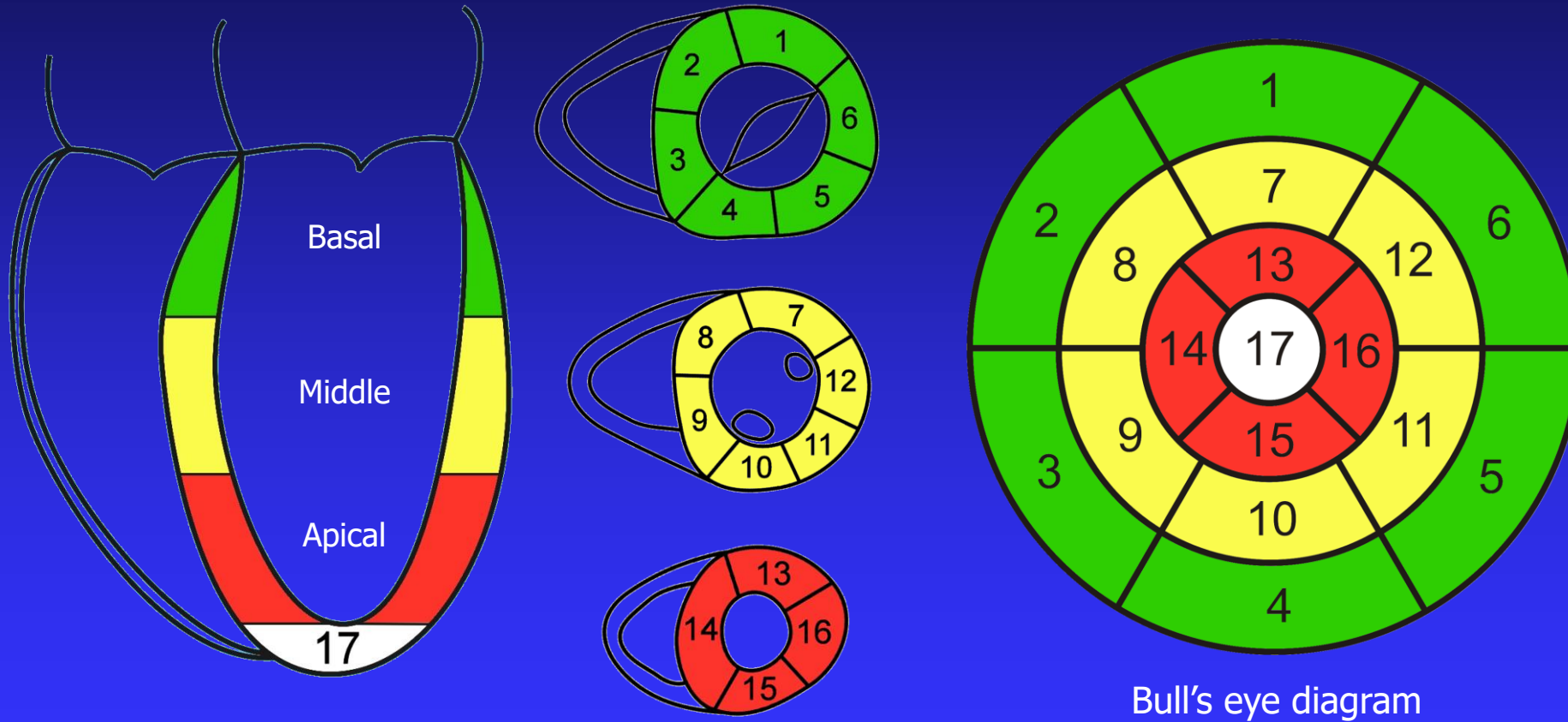


# Globális bal és jobb kamra szisztolés funkció





# Regionális bal kamra funkció





# Regionális bal kamra funkció

<b>1 - Normokinesis</b>	<b>&gt; 40%</b>
<b>2 - Hypokinesis</b>	<b>&lt; 30%</b>
<b>3 - Akinesis</b>	<b>&lt; 10%</b>
<b>4 - Dyskinesis</b>	
<b>5 - Aneurysma</b>	



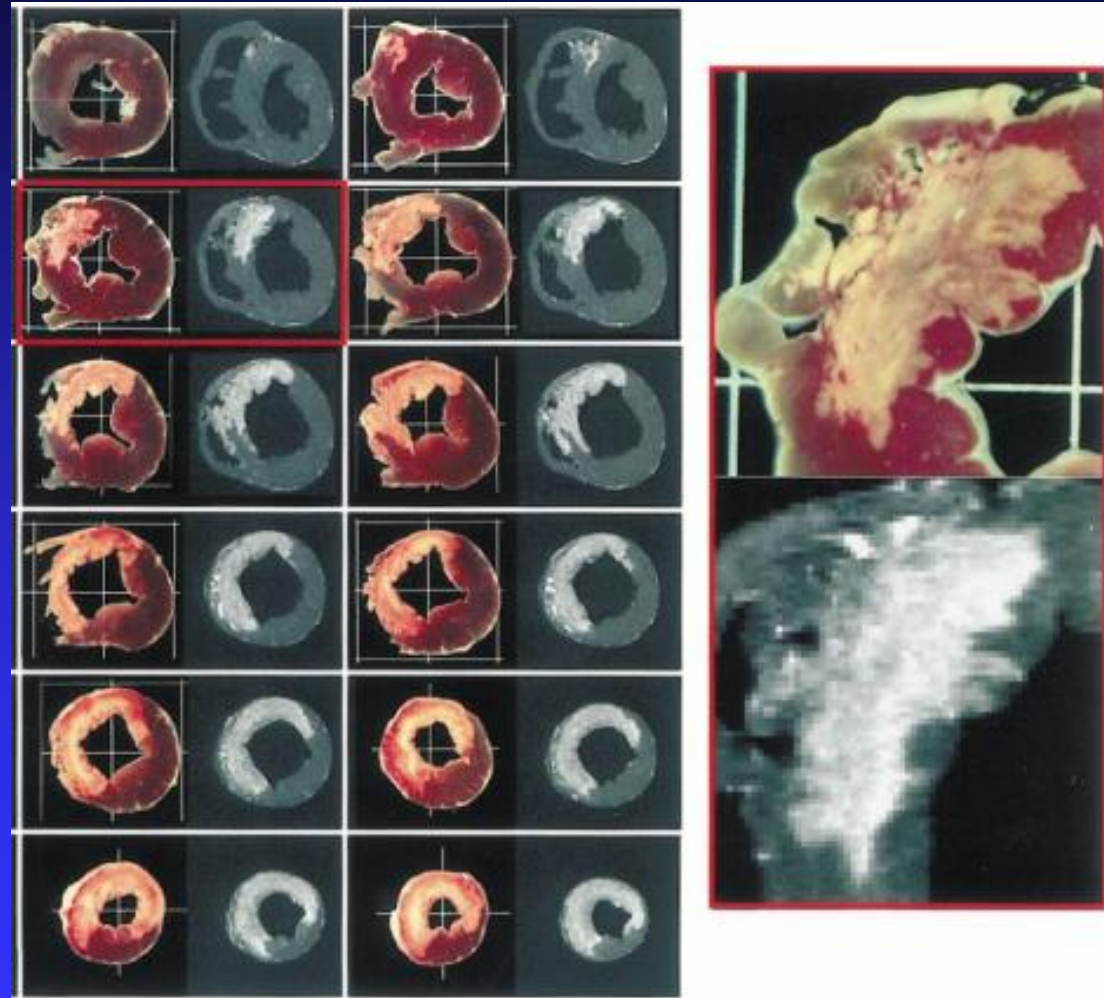
## Késői kontraszt halmozás (LGE)

### IN VIVO

- 10 – 20 min post Gd DTPA
- Inversion recovery FLASH or True-FISP
- “Bright is dead”
- Normal, stunned, hibernating myocardium is dark

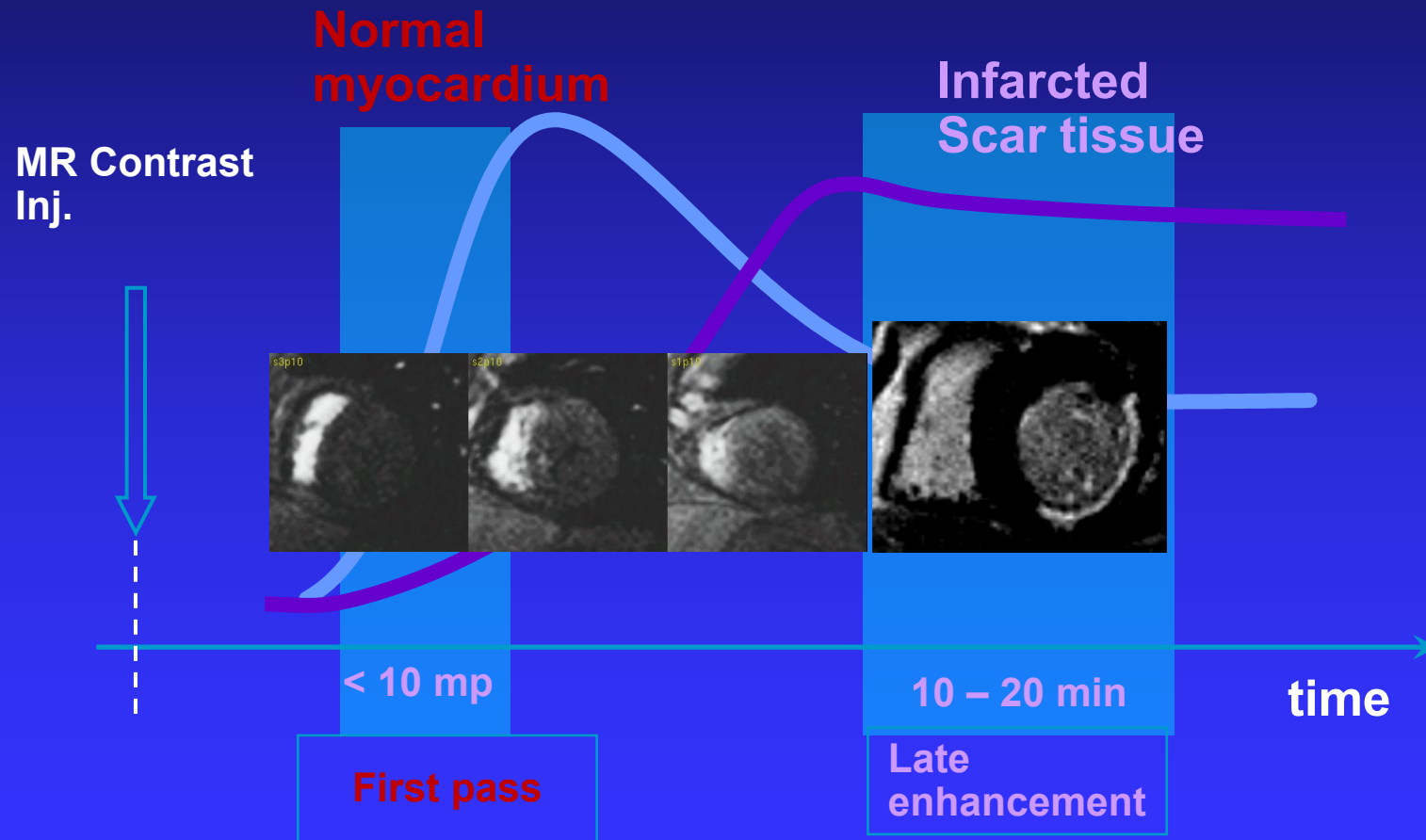
### EX VIVO

- TTC staining



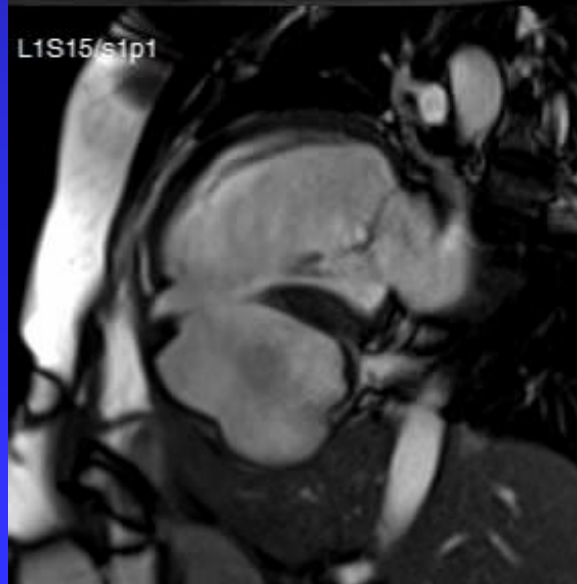
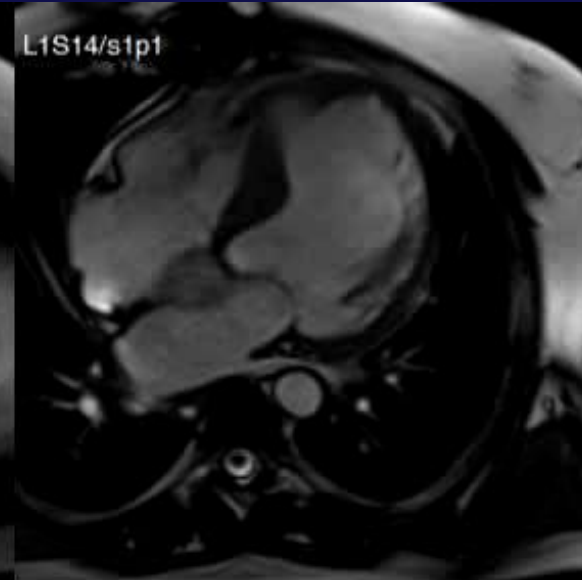
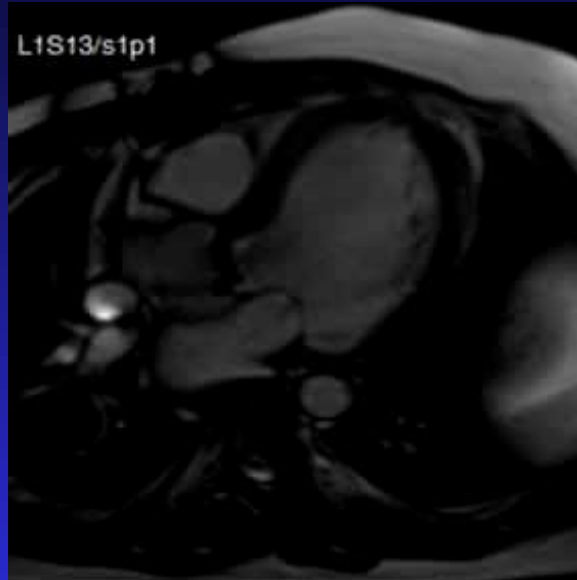


# Perfúziós MRI és késői kontraszt halmozás

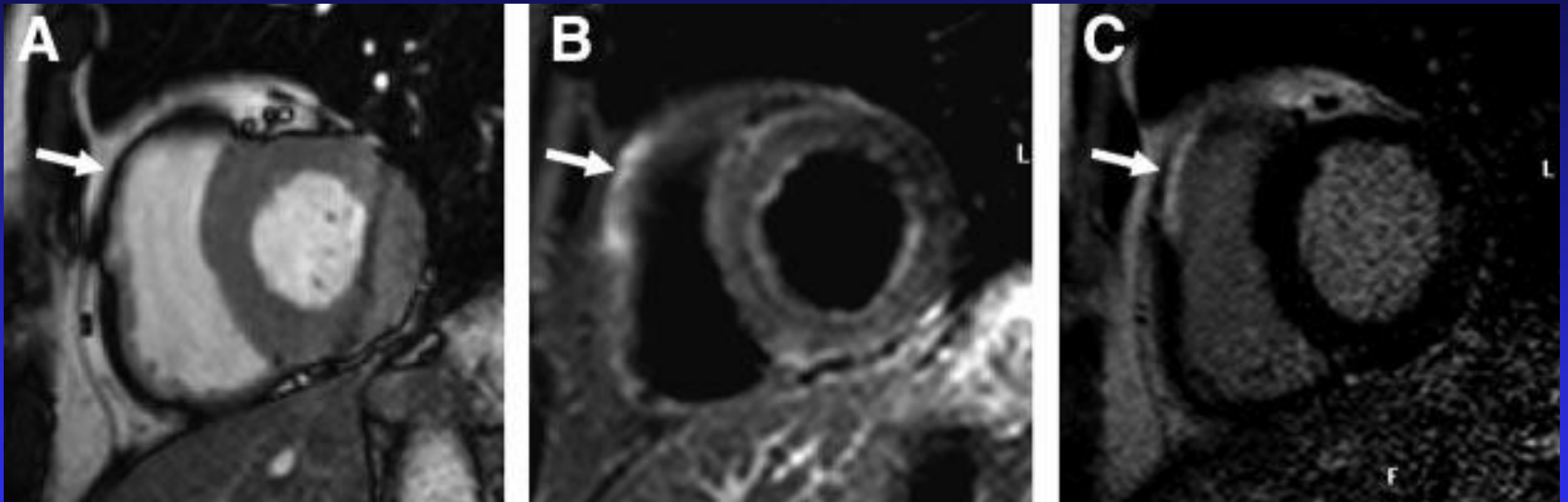




# Csúcsi aneurysma (pseudo)

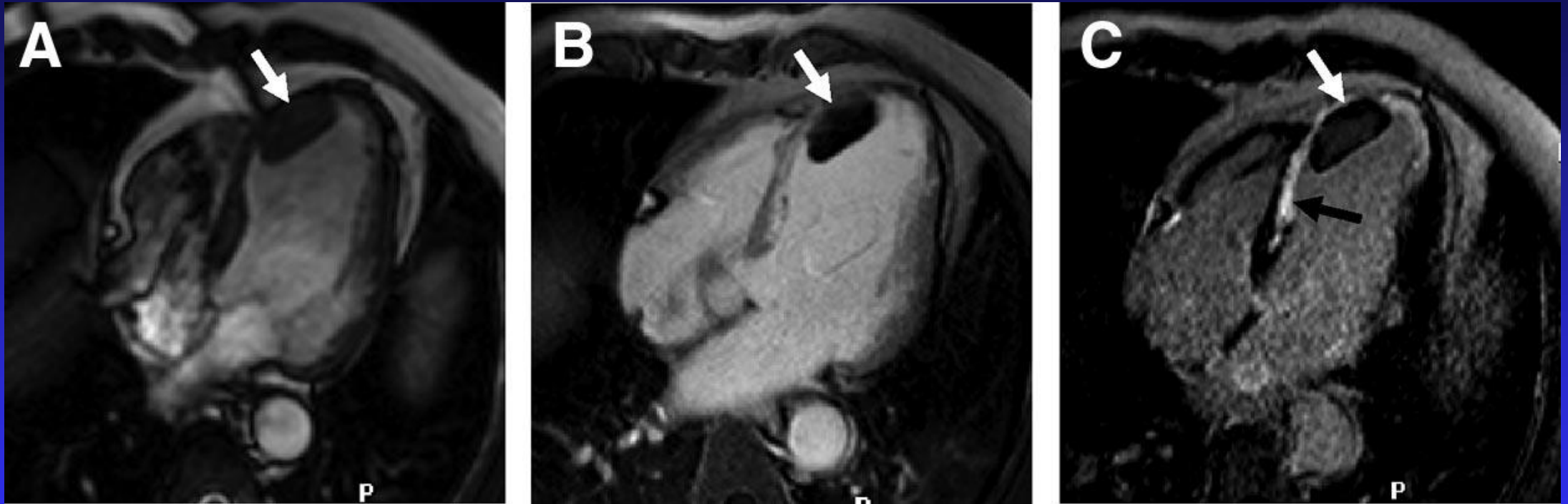


# Jobb kamrai szívinfarktus



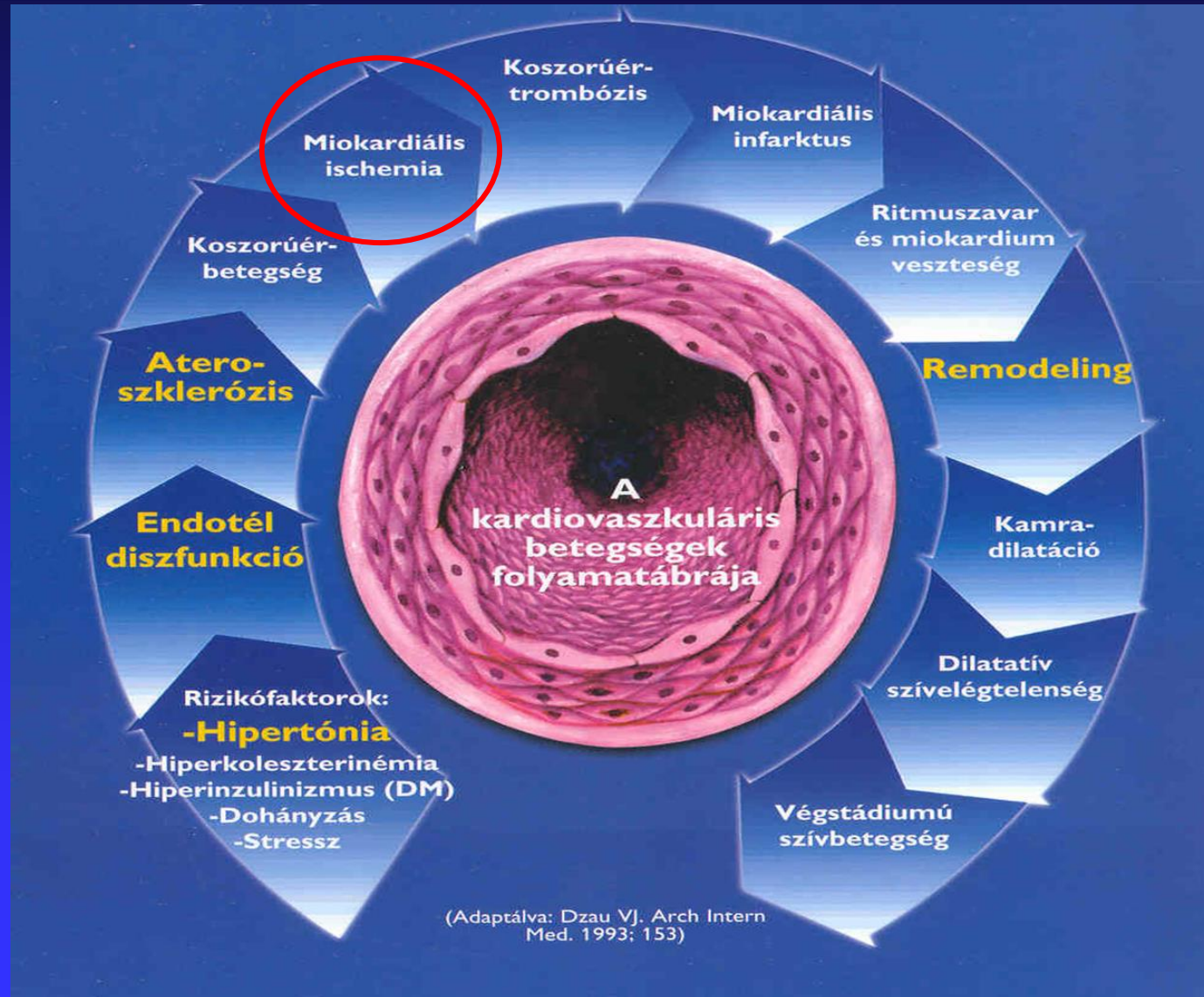
- ❑ CMR images from a patient with acute non-STEMI, evidenced by a rise in cardiac enzymes and nonspecific ST-segment changes on an ECG. Invasive coronary angiography revealed 3-vessel CAD with an occluded proximal RV branch of the right coronary artery.
- ❑ A cine CMR image (A) in systole shows a subtle wall motion abnormality in the anterior RV free wall (arrow).
- ❑ The T2-weighted image (B) shows high signal in this area with corresponding high signal on the
- ❑ late gadolinium-enhanced image (C). There is no evidence of scar in the left ventricle, suggesting isolated RV infarction

# Szívinfarktus szövődmény



- ❑ CMR images in the 4-chamber orientation from a patient with previous anteroseptal MI.
- ❑ A, The diastolic frame from a cine CMR study shows thinning of the interventricular septum with a mass lesion at the endocardial surface (arrow).
- ❑ B, Early gadolinium-enhanced images show that the lesion does not take up contrast.
- ❑ C, Late gadolinium-enhanced images delineate the extent of MI (black arrow) as hyperenhancement and show that the lesion remains unenhanced (white arrow), suggesting an LV thrombus.

# Kardiovaszkuláris betegségek folyamatábrája



MRI szerepe



# Stressz teszt

EKG  
Echo  
MRI  
SPECT





# Stress test

**Table 12** Characteristics of tests commonly used to diagnose the presence of coronary artery disease

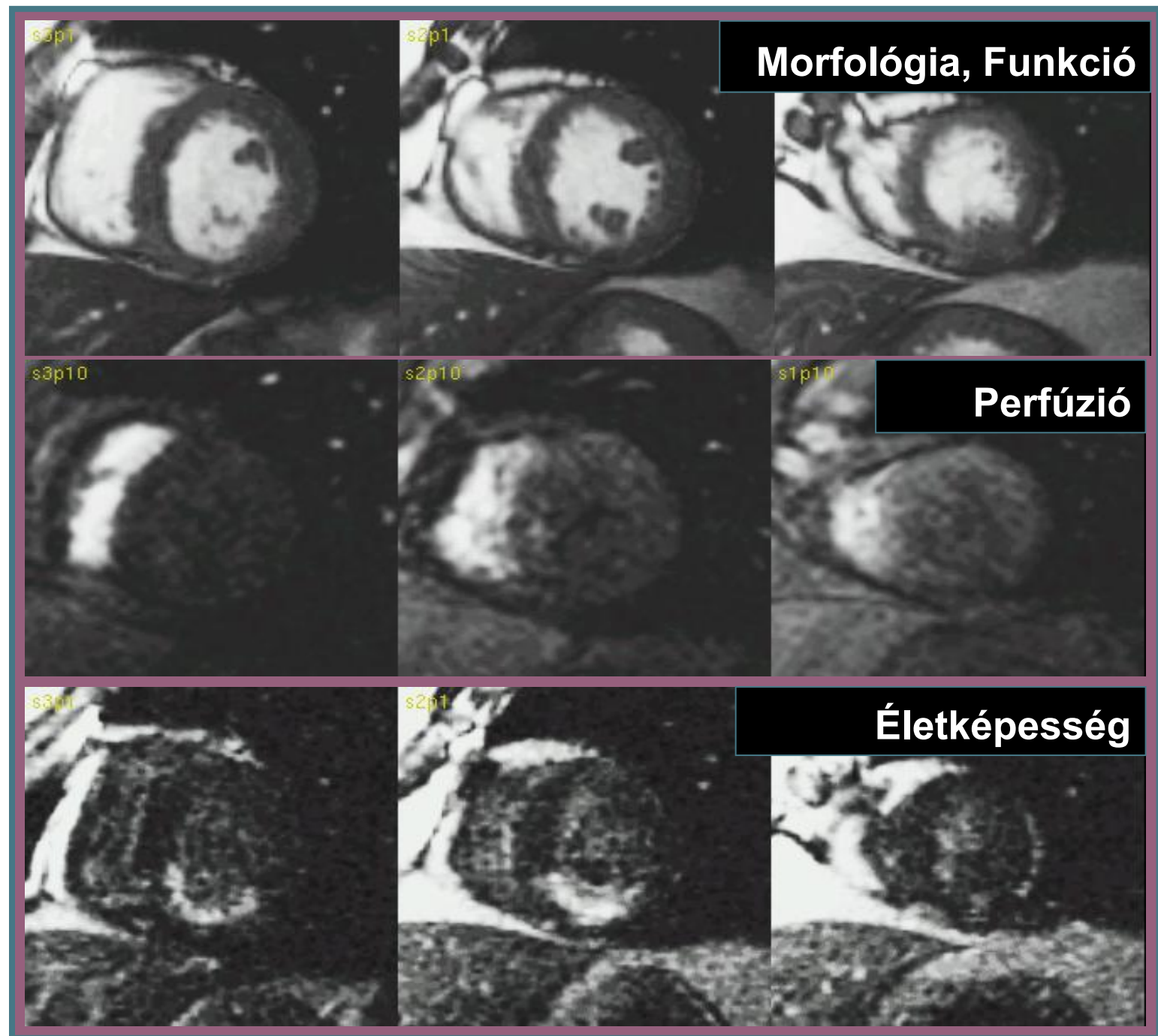
	Diagnosis of CAD	
	Sensitivity (%)	Specificity (%)
Exercise ECG <sup>a, 91, 94, 95</sup>	45–50	85–90
Exercise stress echocardiography <sup>96</sup>	80–85	80–88
Exercise stress SPECT <sup>96-99</sup>	73–92	63–87
Dobutamine stress echocardiography <sup>96</sup>	79–83	82–86
Dobutamine stress MRI <sup>b, 100</sup>	79–88	81–91
Vasodilator stress echocardiography <sup>96</sup>	72–79	92–95
Vasodilator stress SPECT <sup>96, 99</sup>	90–91	75–84
Vasodilator stress MRI <sup>b, 98, 100-102</sup>	67–94	61–85
Coronary CTA <sup>c, 103-105</sup>	95–99	64–83
Vasodilator stress PET <sup>97, 99, 106</sup>	81–97	74–91

# Adenozin stressz CMR 2026 előtt

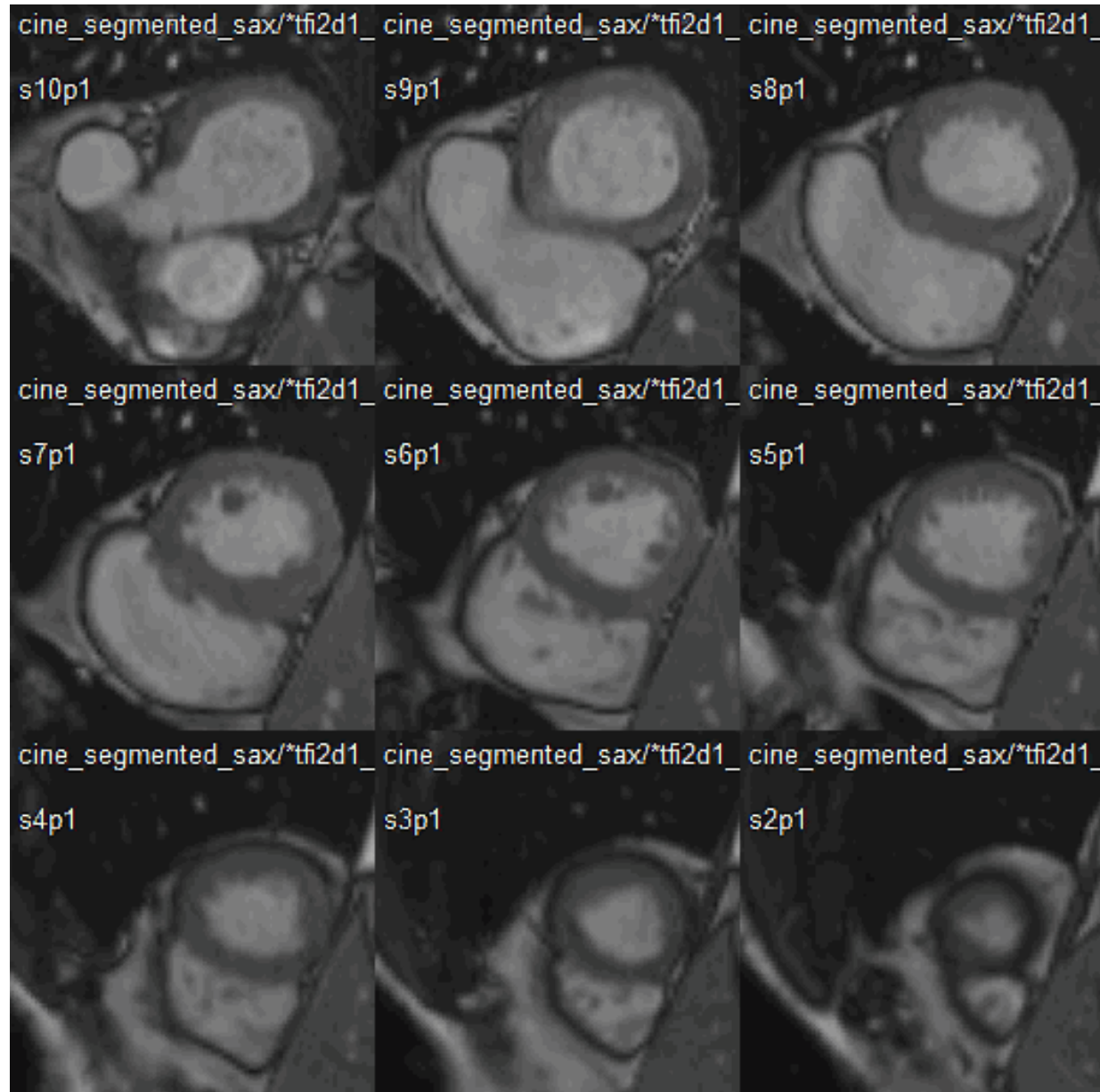
Cine CMR rövid tengely

Adenozin stressz CMR

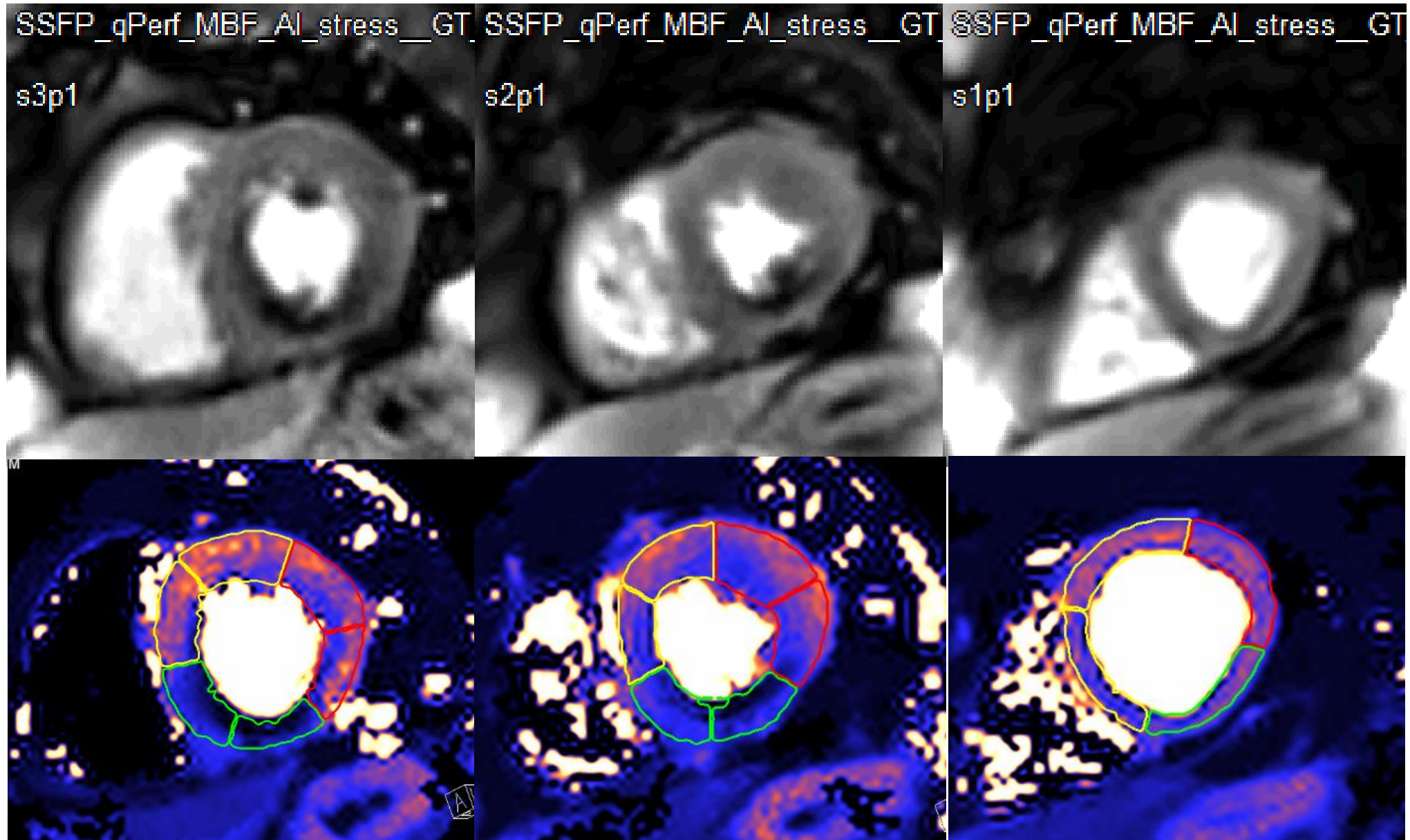
LGE



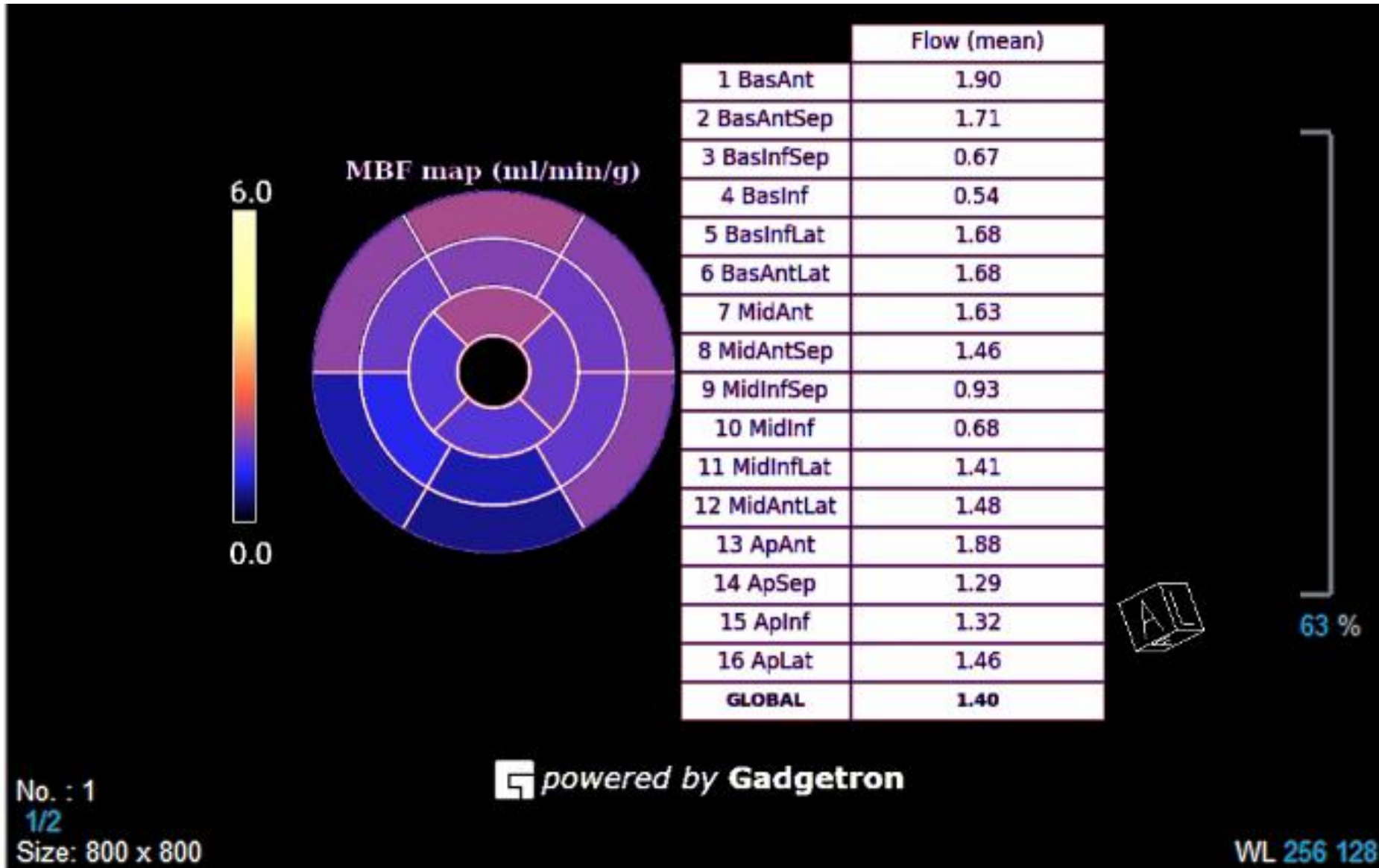
## 2. beteg: cine CMR rövid tengely felvételek



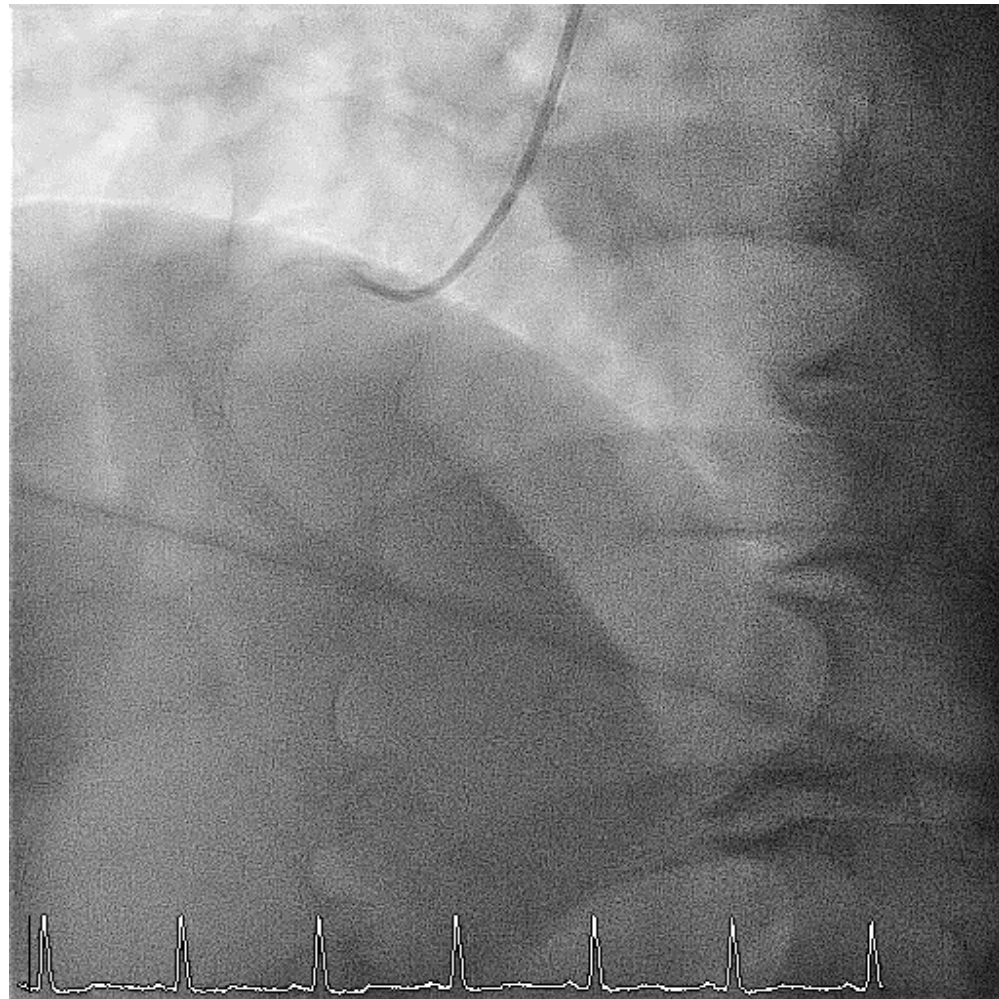
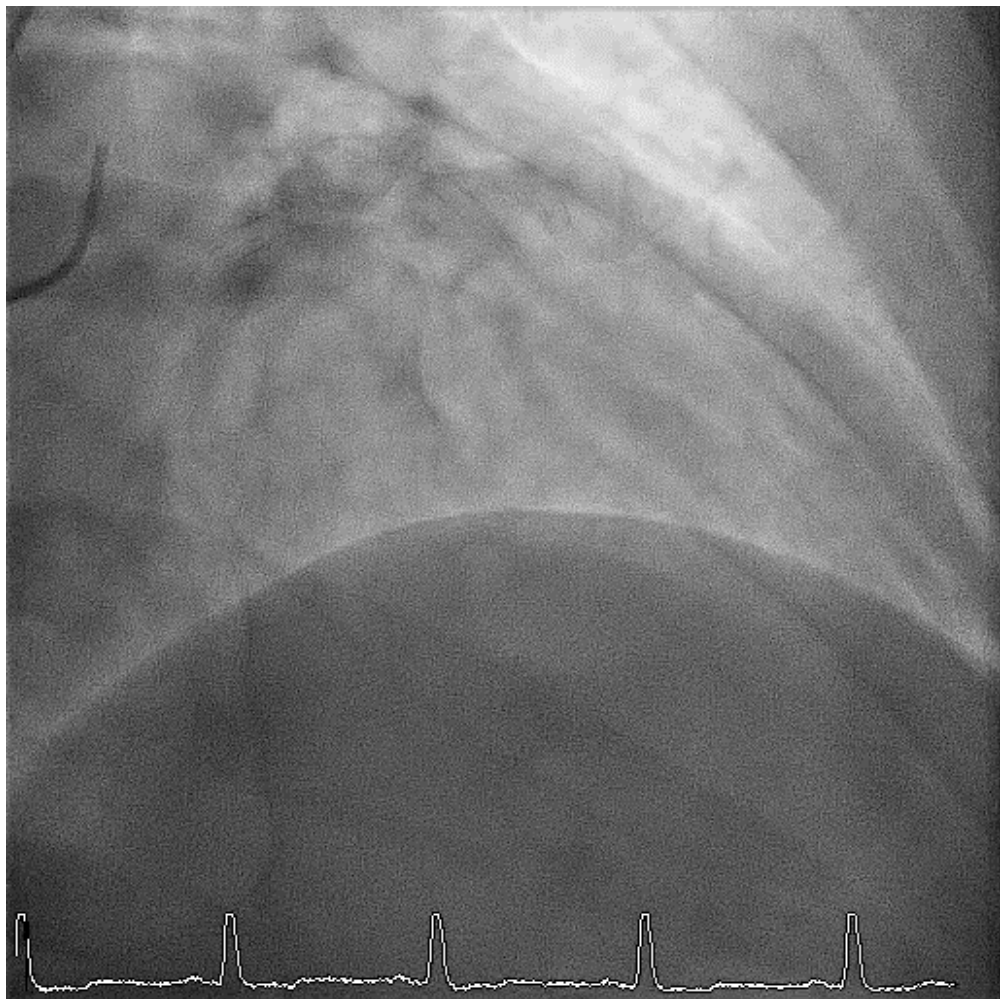
# Adenozin stressz CMR – rövid tengely felvételek



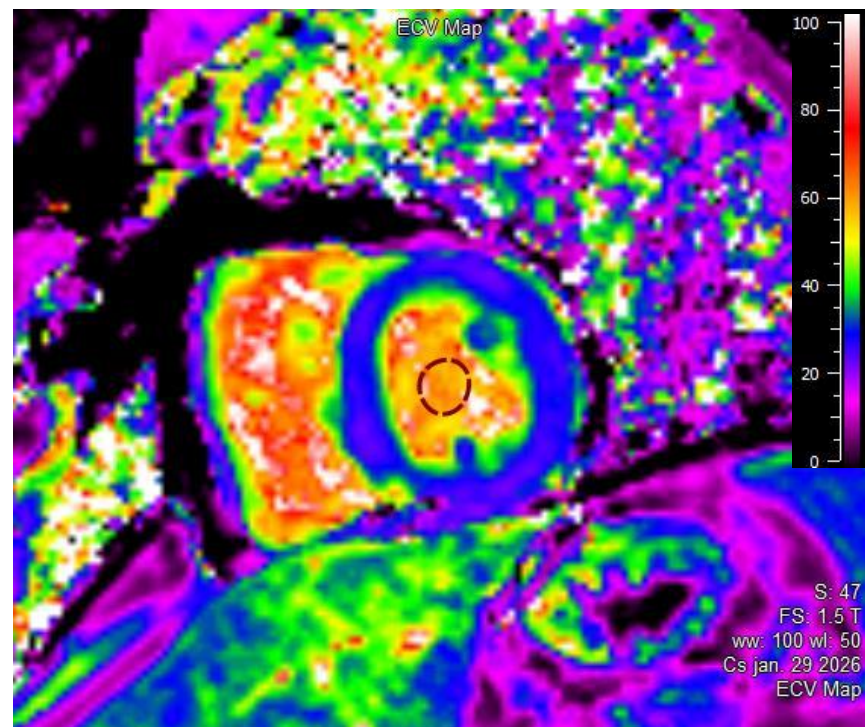
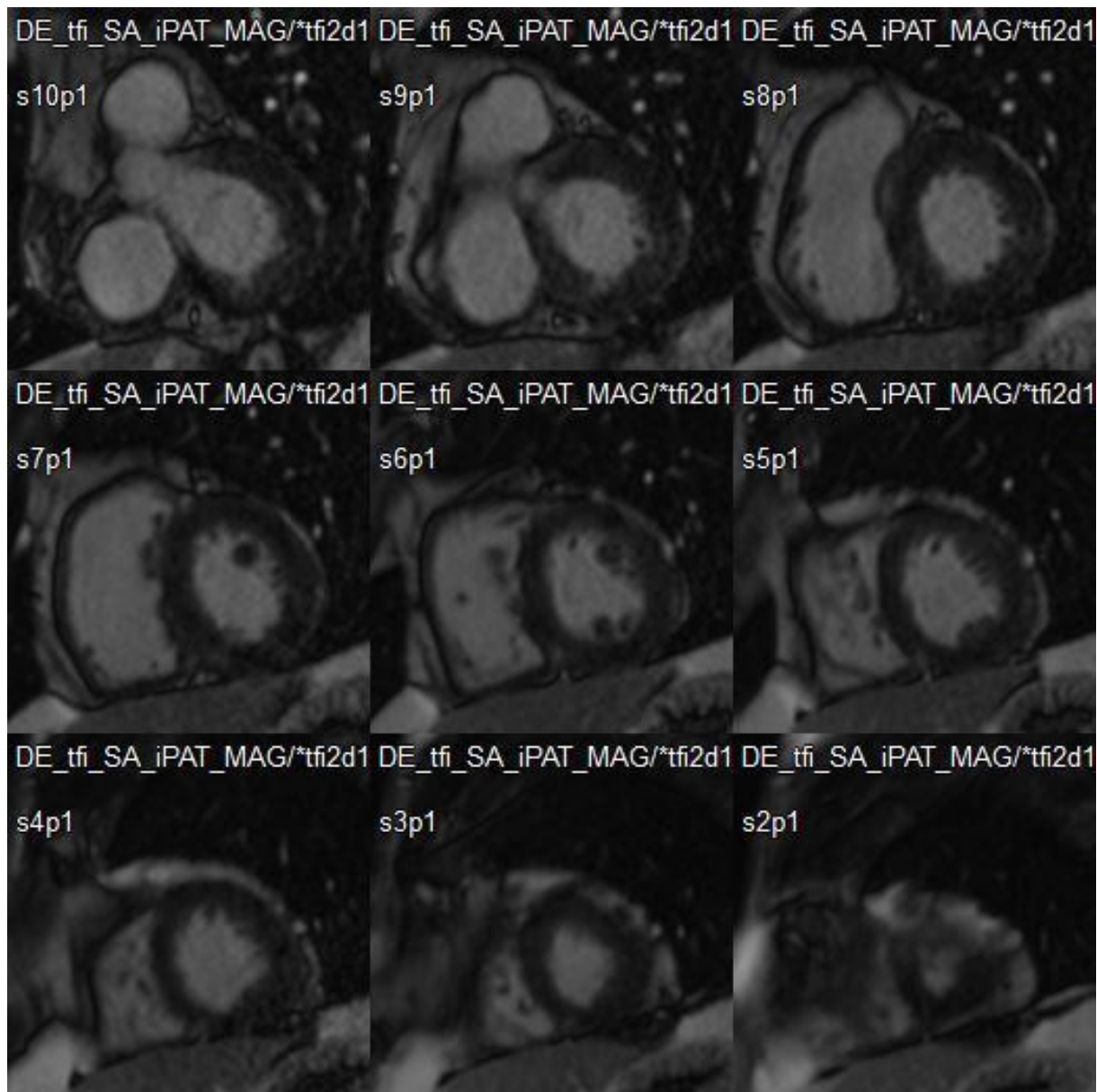
# Adenozin stressz CMR - Myocardium blood flow map (MBF) quantitativ meghatározás



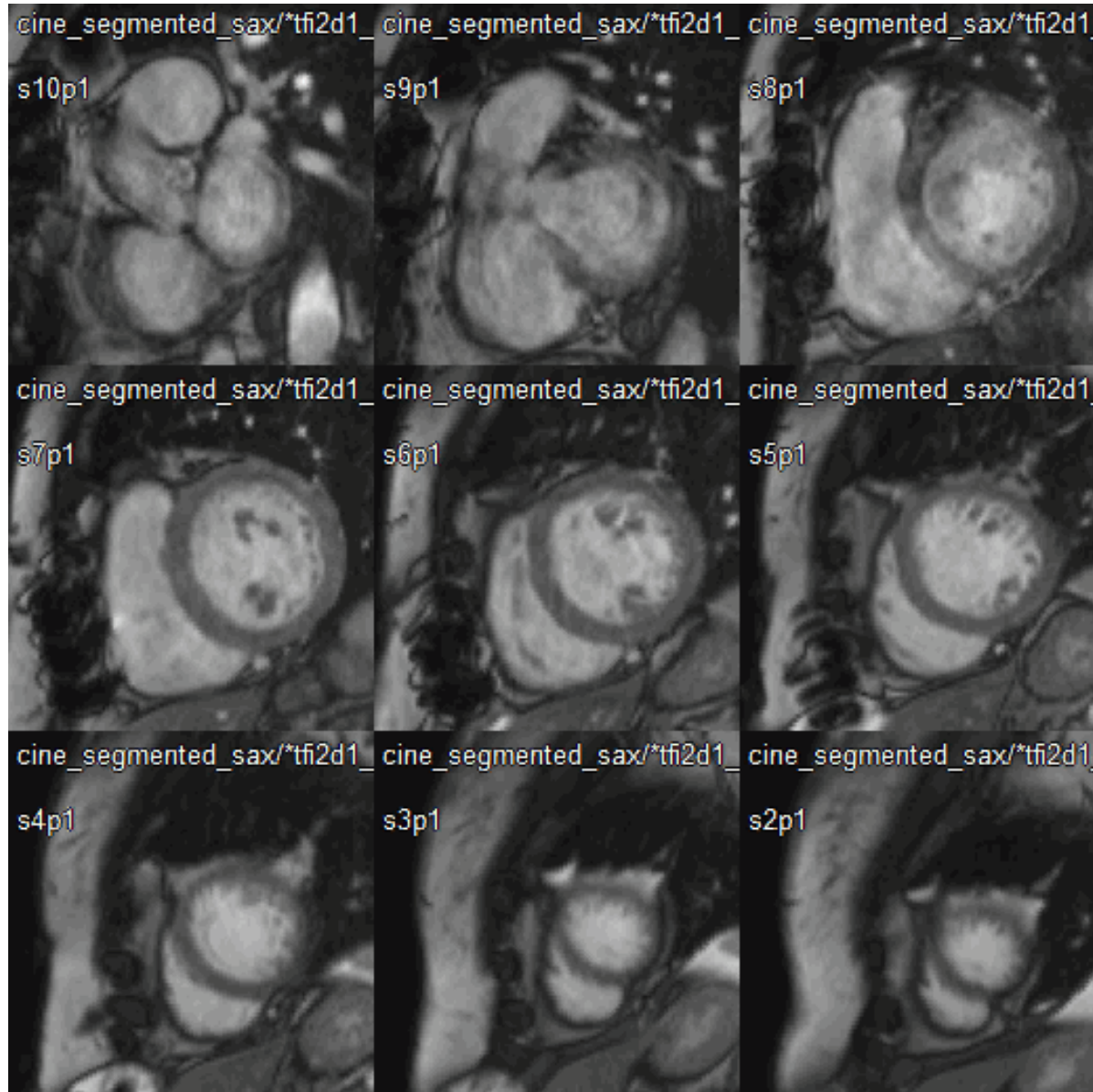
# Coronarographia



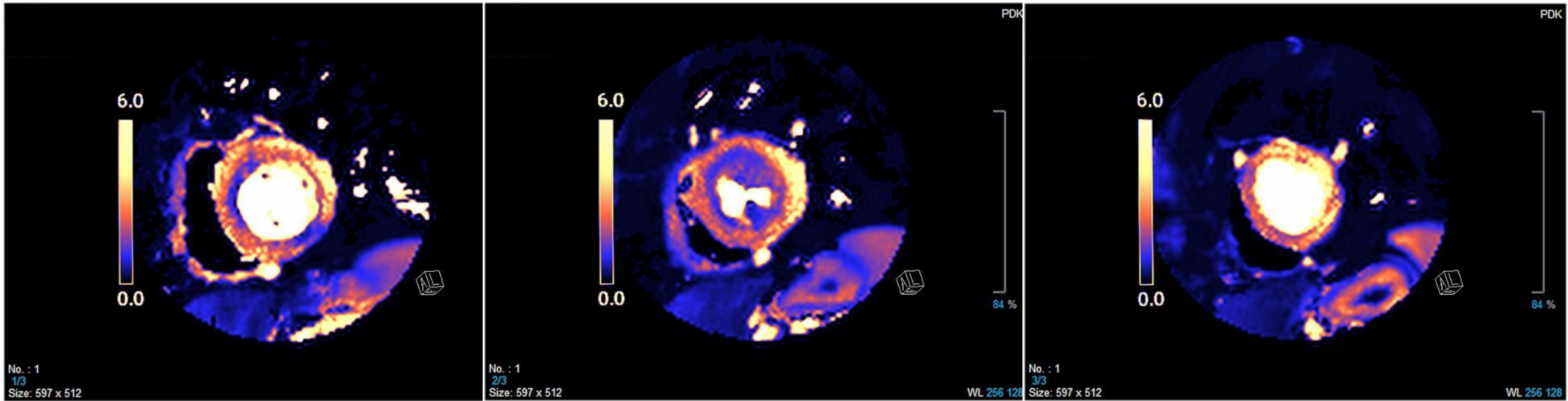
# LGE - késői kontraszt halmozás és ECV meghatározás– rövid tengely



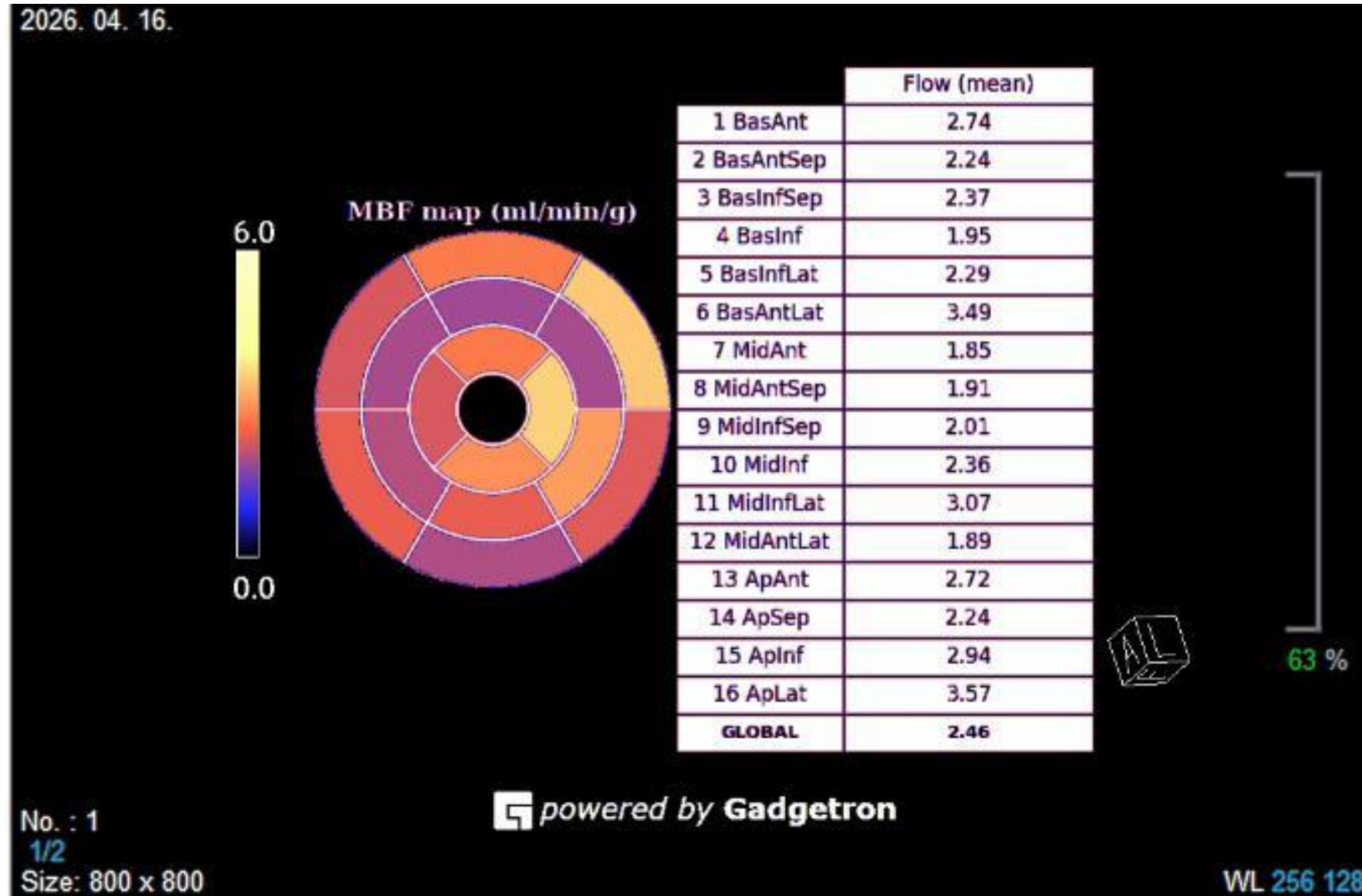
### 3. beteg: cine rövid tengely felvételek



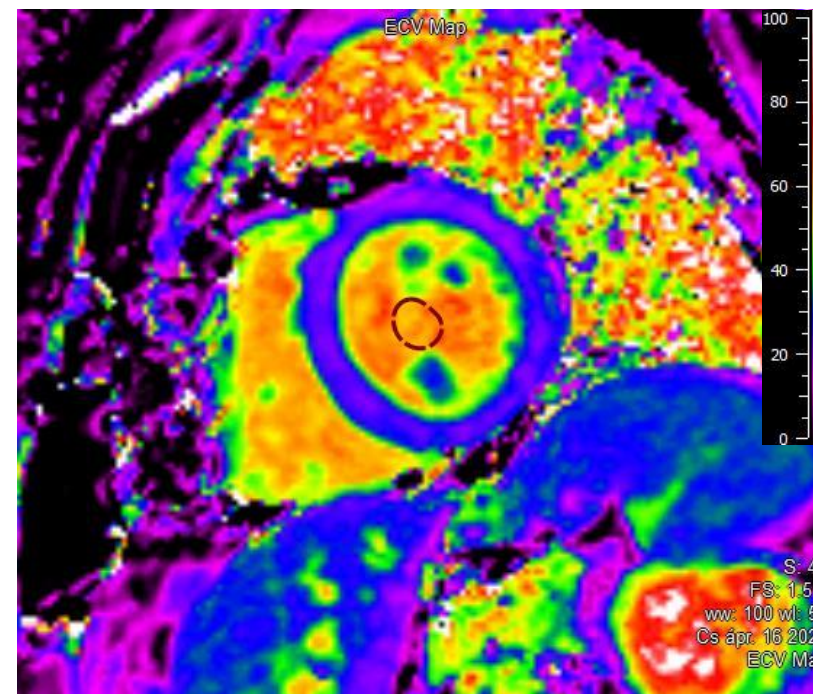
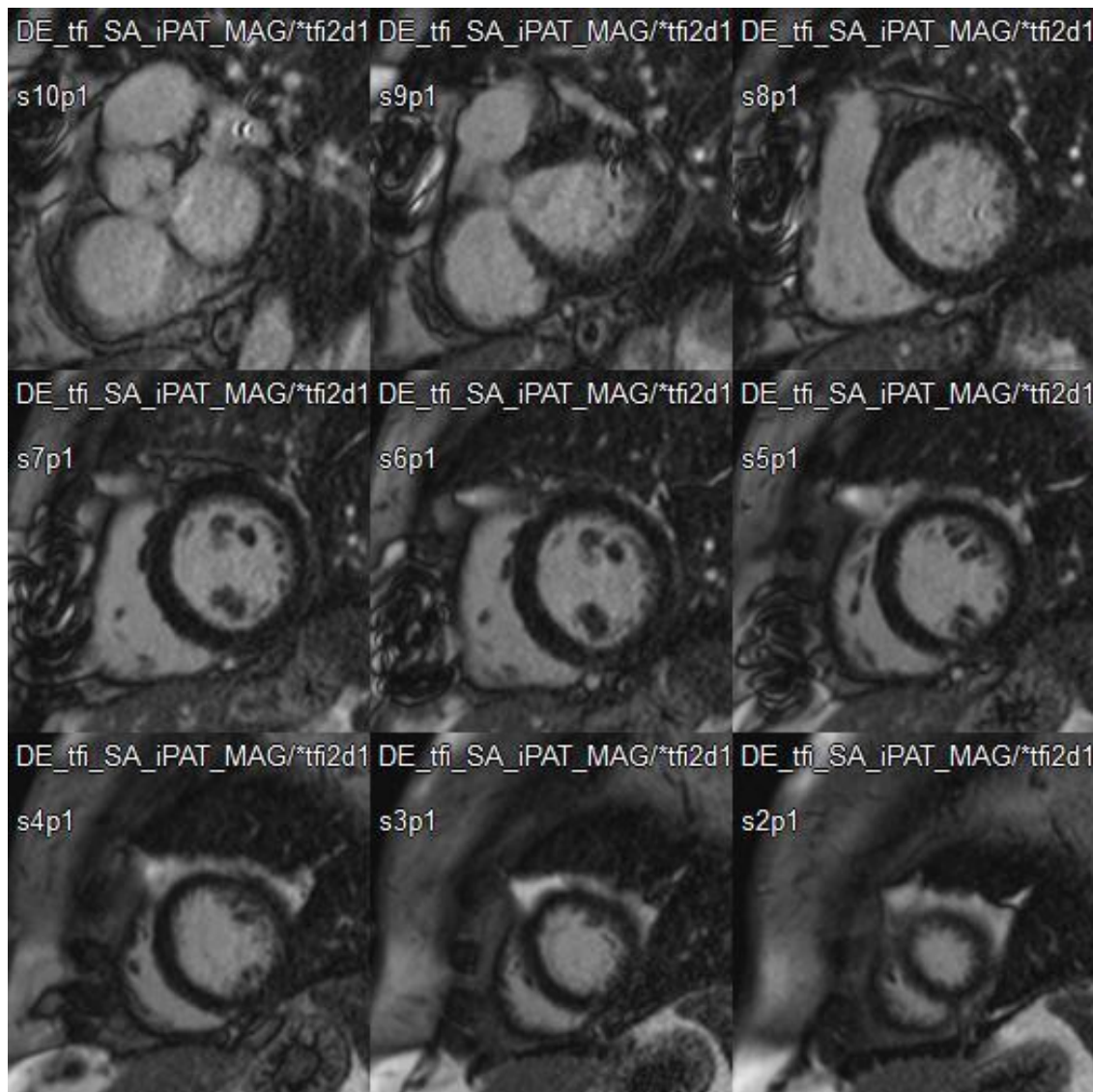
# Adenozin stressz CMR – rövid tengely felvételek



# Adenozin stressz MRI - Myocardium blood flow map (MBF) quantitativ meghatározás

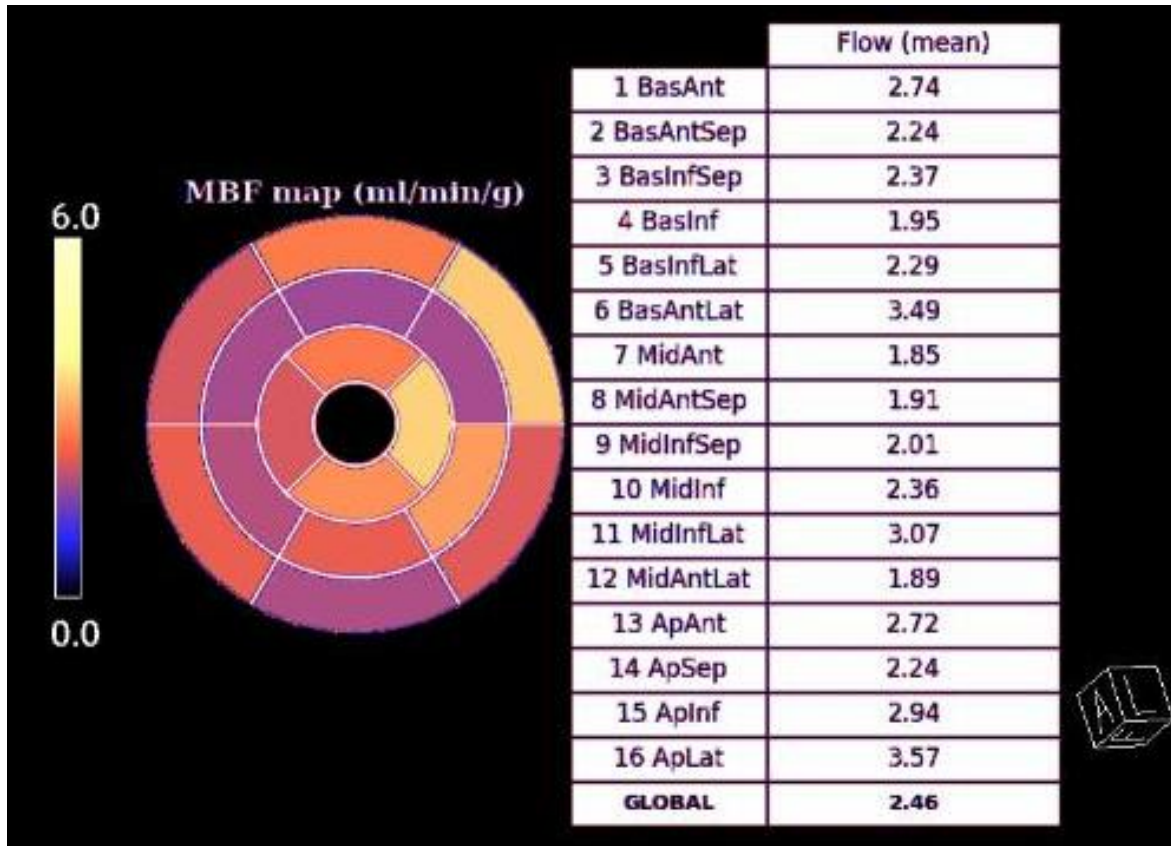


# LGE késői kontraszt halmozás és ECV meghatározás– rövid tengely




# Adenozin stressz MRI - Myocardium blood flow map (MBF) quantitativ meghatározás

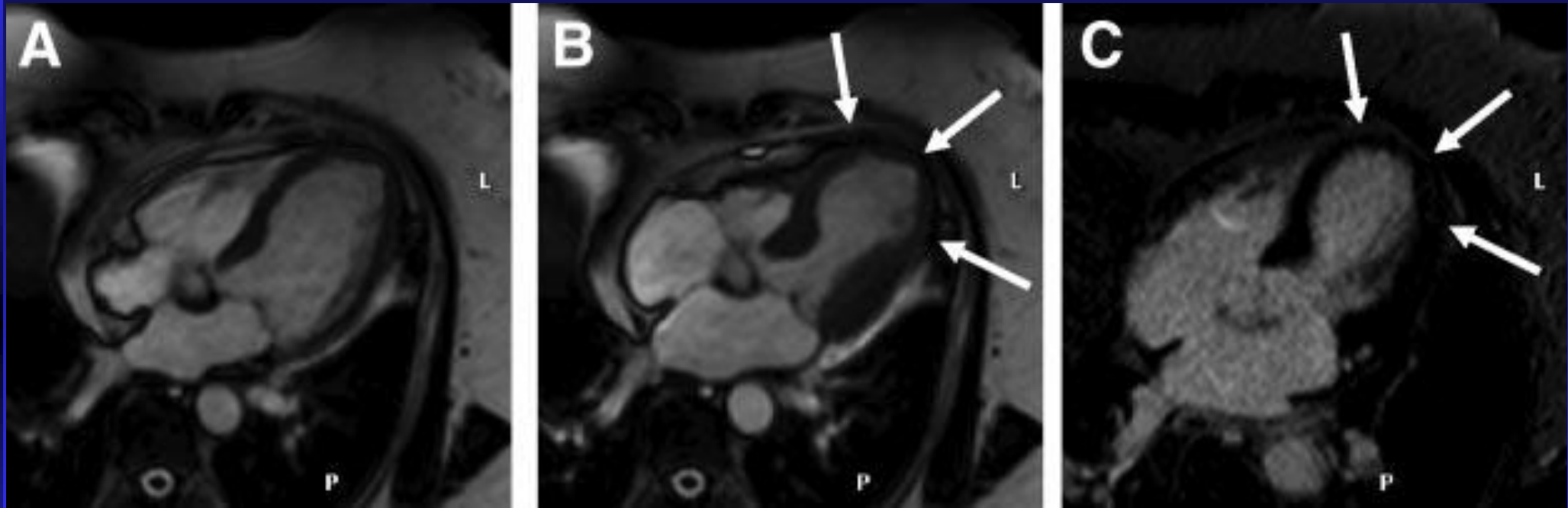
3. beteg



2. beteg

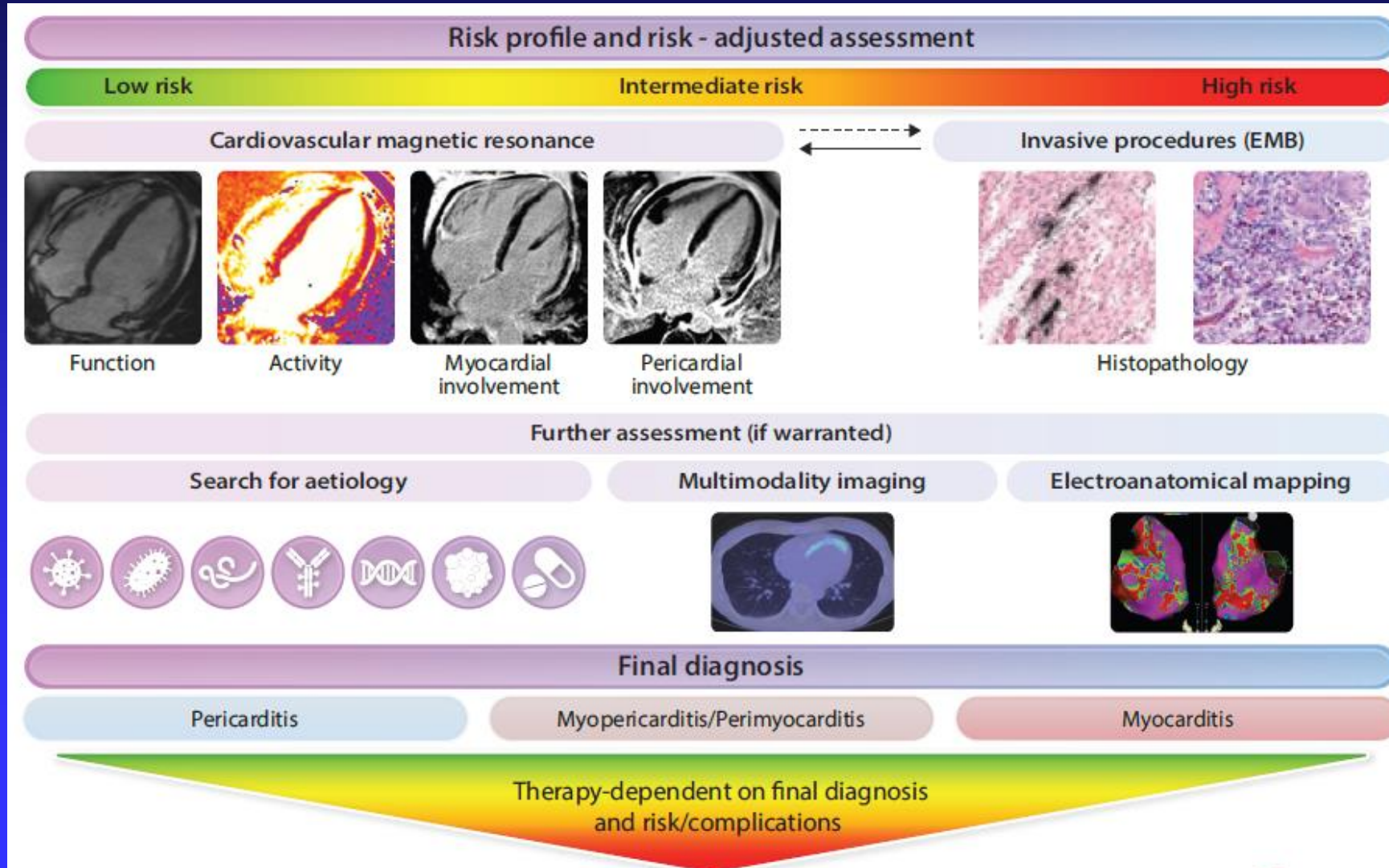


# Takotsubo szindróma

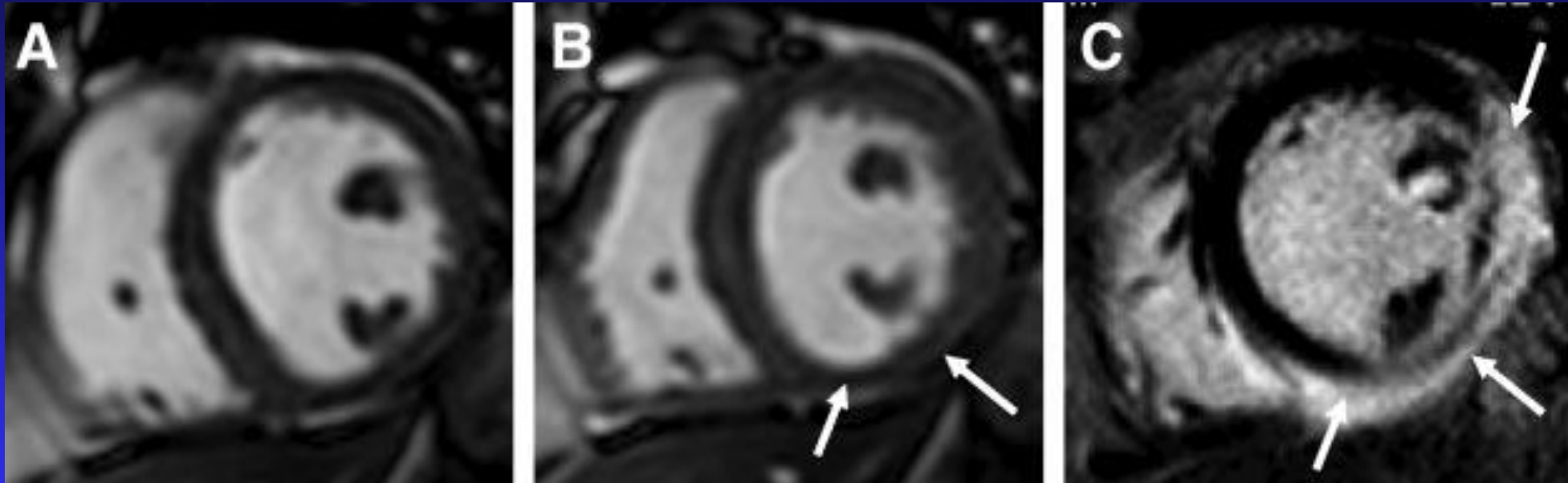




# 2025 ESC Guidelines for the management of myocarditis and pericarditis



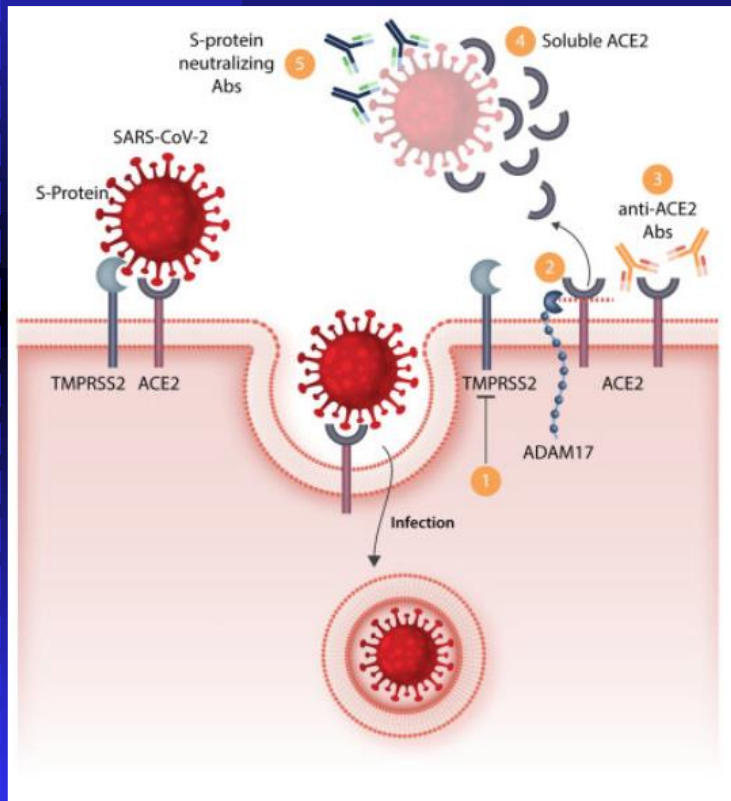
# Akut szívizomgyulladás



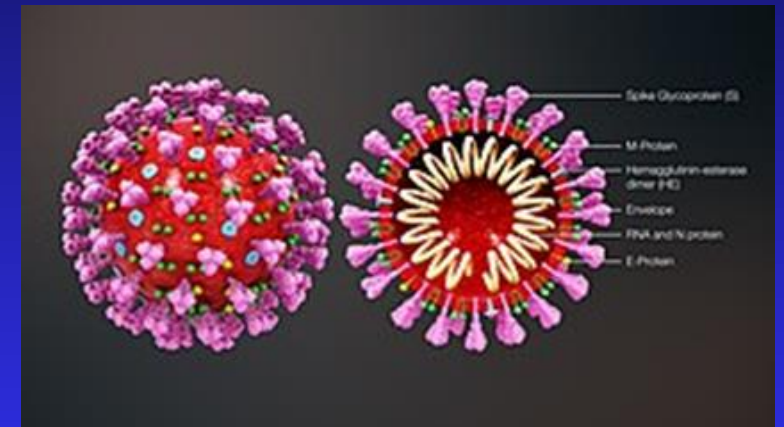
- ❑ CMR images from a 49-year-old woman presenting with chest pain and breathlessness. Cardiac serum biomarkers were raised, and an ECG showed widespread T-wave inversion. Coronary angiography showed normal coronary arteries with no evidence of coronary atheroma.
- ❑ CMR shows a regional wall motion abnormality predominantly in the inferior segments (A, diastole; B, systole). Late gadolinium enhancement images (C) show extensive epicardial hyperenhancement in the inferior and near-transmural enhancement in the lateral segments. Based on all available results, a clinical diagnosis of myocarditis was made. The patient declined cardiac biopsy.



# COVID-19 pandémia és kardiovaszkuláris szövődményei

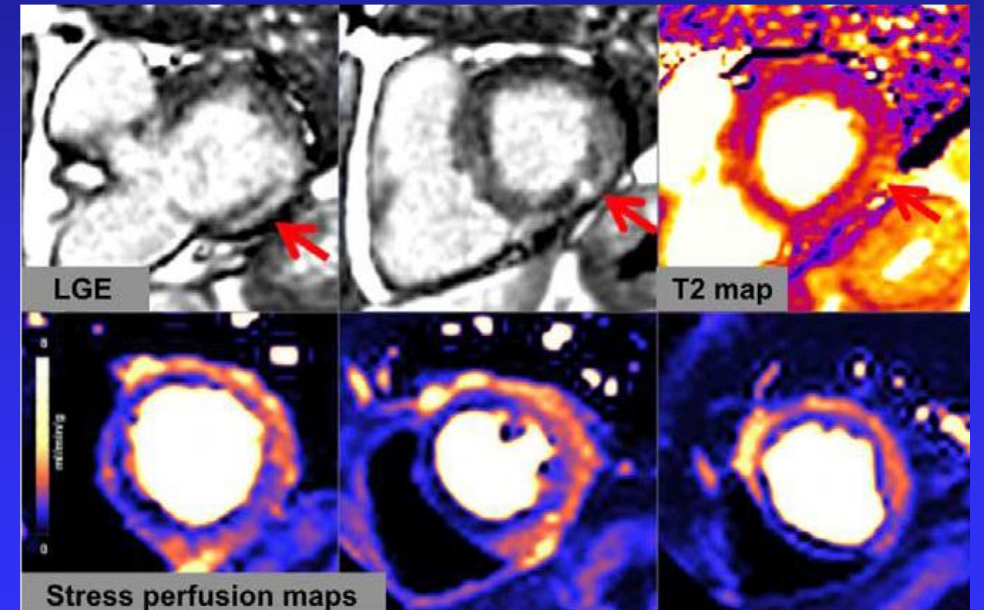
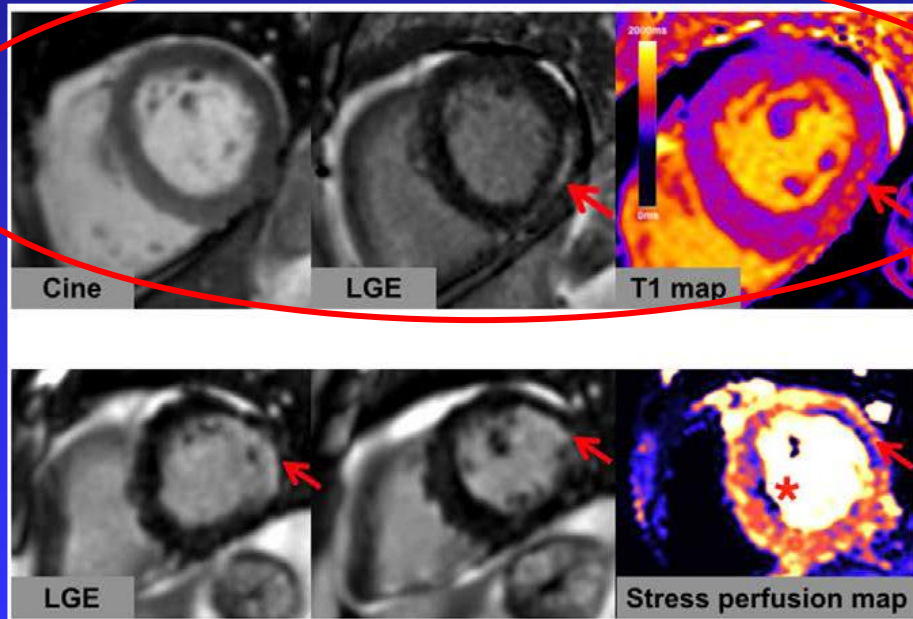


- 2020 január óta a világon  
> 218 millió beteg  
> 4.5 millió halálozás
- Magyarországon  
> 812.000 fertőzött  
> 30.059 halálozás



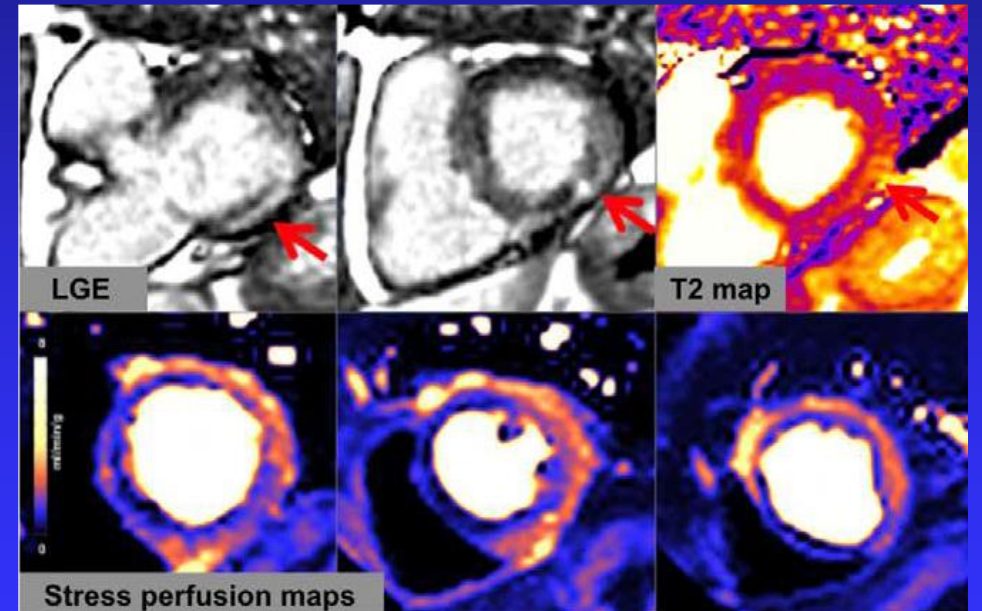
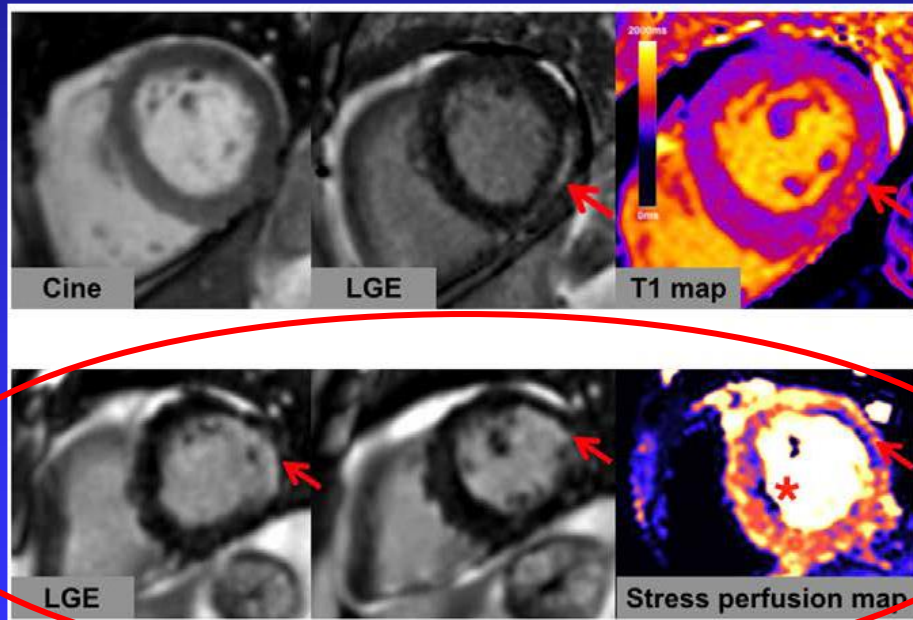
- Mit tudunk a SARS-CoV 2-ről?  
RNS vírus, ACE2 receptorokon jut a gazdasejtbe  
> 169.234 publikáció (PubMed)

# Miokardium sérülés mechanizmusai: miokarditisz és iszkémia egyaránt

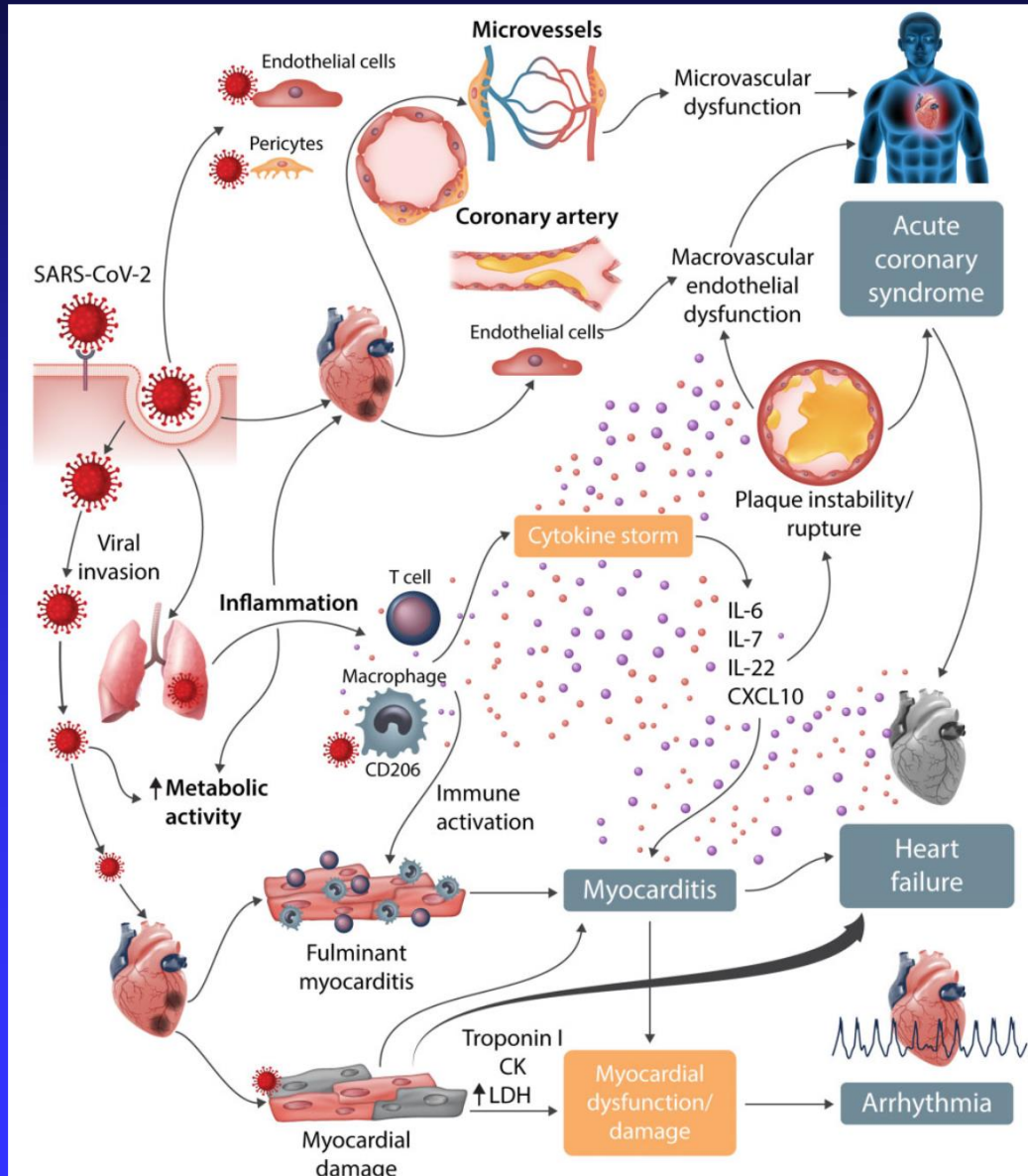




# Miokardium sérülés mechanizmusai: miokarditisz és iszkémia egyaránt



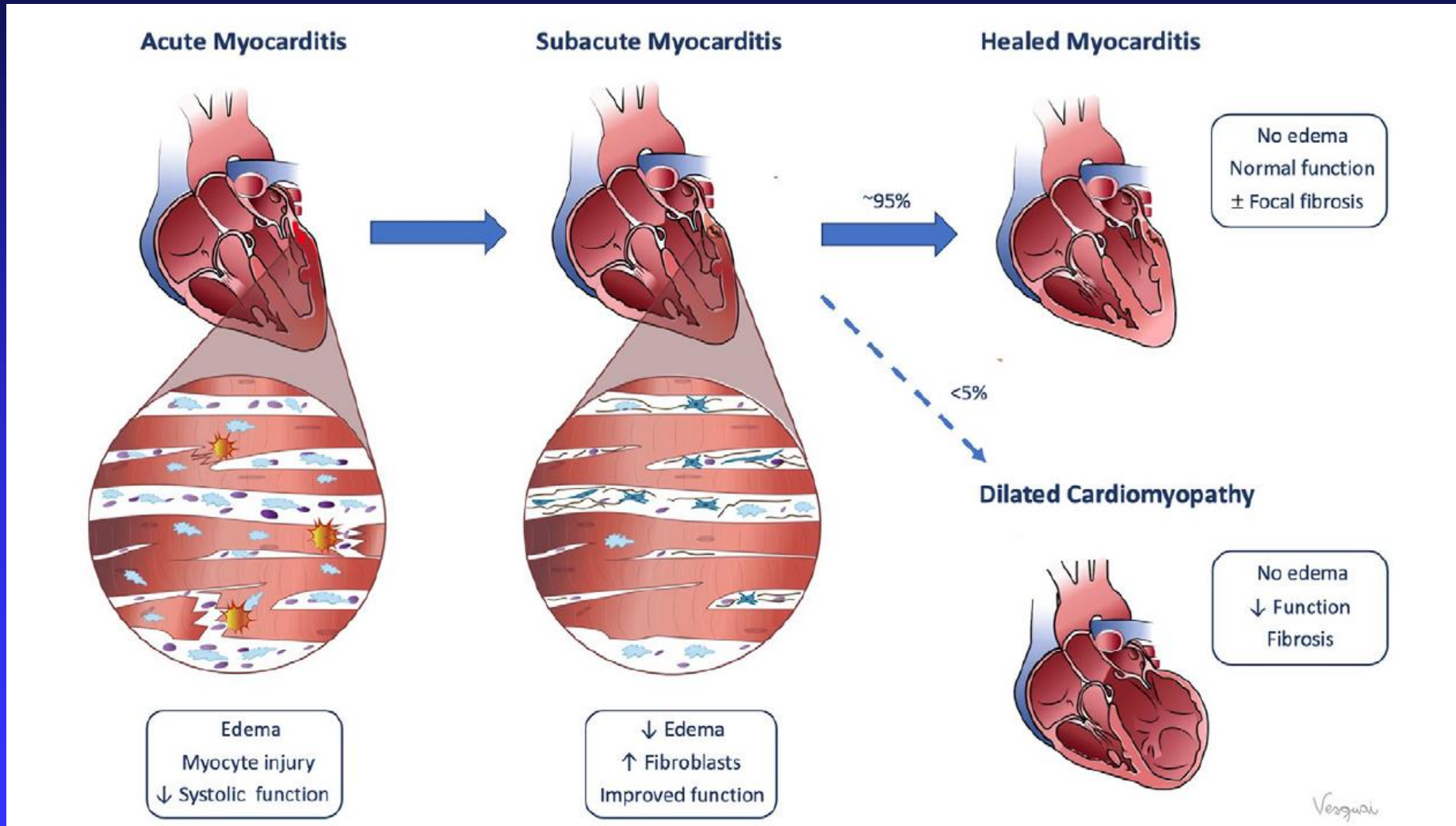
# Myocardium károsodás kórélettana



- ACS
- Myocarditis (citokin vihar)
- Malignus kamrai ritmuszavar (VT, VF)
- AV blokk
- Akut szívelégtelenség



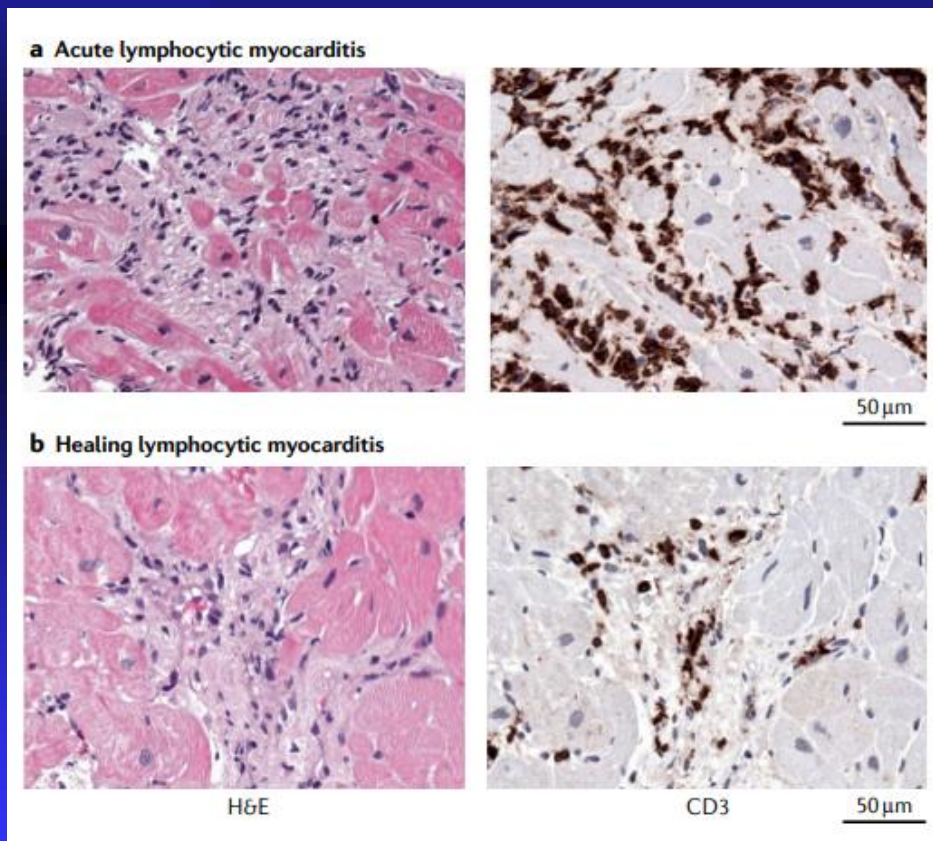
# Myocarditis kórlefolyása – MRI modalitások





# Myocarditis és gyulladásos cardiomyopathiák

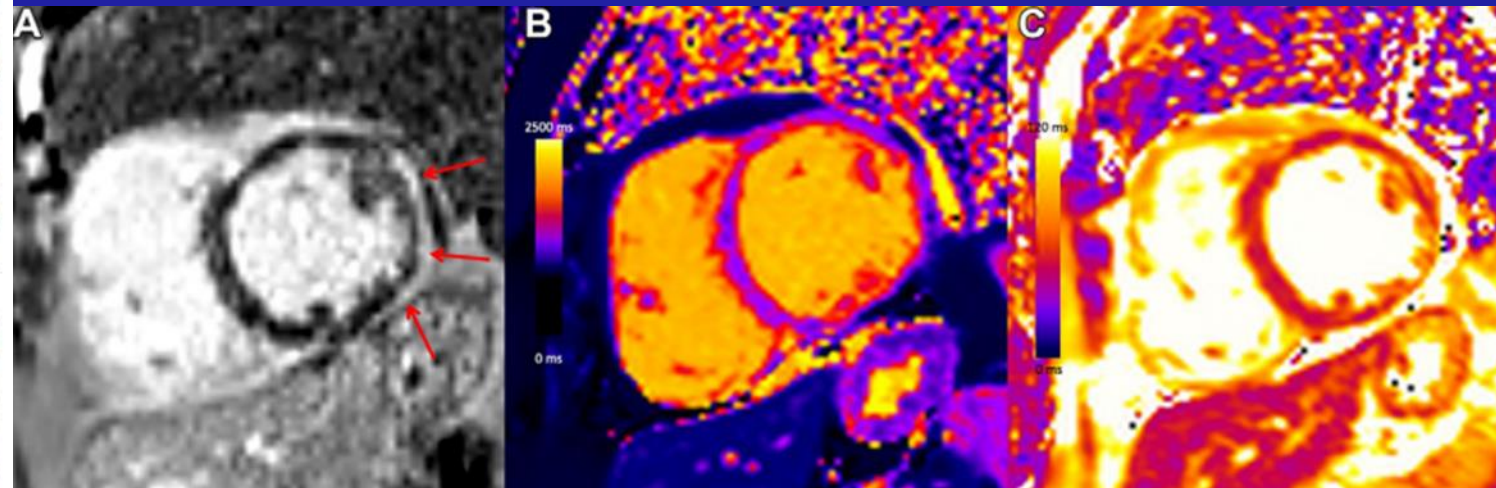
új MRI modalitások: lokális vagy diffúz eltérések, kvantitatív értékeléssel



LGE

T1 mapping, ECV

T2 mapping





# Myocarditis diagnózisa módosított Lake Louise kritériumokkal

- EKG: ST-T eltérések (ACS szerű)
- Labor: hs Troponin, CRP, vírus szerológia
- Echo: tág bal kamra, falmozgászavar – globális, szegm. egyéb okok pericardialis folyadék
- MRI: oedema hyperemia necrosis, fibrosis (non-ischemiás) falmozgászavar
- Biopsia

**TABLE 1** Diagnostic Tests and Potential Findings in Patients With Acute Myocarditis\*

ECG, Holter, or stress test

- AV block I-III, bundle branch block, sinus arrest
- Extrasystoles
- Supraventricular tachycardia, atrial fibrillation
- Ventricular tachycardia, ventricular fibrillation, asystole
- ST-segment and T-wave changes (ST-segment elevation, T-wave inversion)
- Intraventricular conduction delay
- New Q waves
- Low voltage

Seromarkers for myocardial necrosis

- Troponin elevation
- Creatine kinase elevation

Cardiac imaging

- Echocardiography/angiography
  - Regional or global systolic or diastolic dysfunction, with or without LV dilatation
  - Increased wall thickness
  - Pericardial effusion
  - Intracavitary thrombi

CMR

- Edema
- Hyperemia or capillary leak (early gadolinium enhancement)
- Irreversible injury (necrosis, scar; late gadolinium enhancement)
- Regional or global systolic or diastolic dysfunction, with or without LV dilatation
- Increased wall thickness
- Pericardial effusion
- Intracavitary thrombi

# Peri- myocarditis MRI diagnózisa

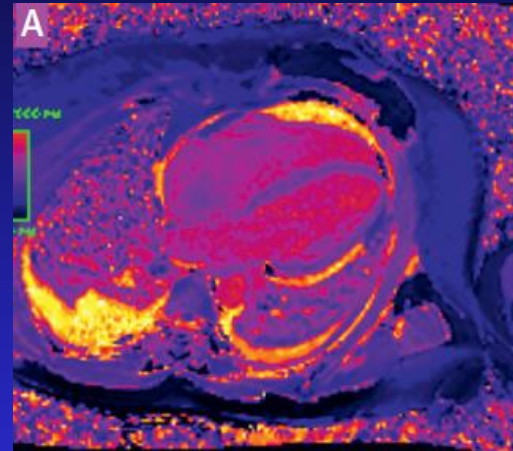
## Myocarditis:

- Funkció - cine
- Oedema - T2
- Hyperemia - T1, ECV
- Necrosis-fibrosis - LGE, T1, ECV

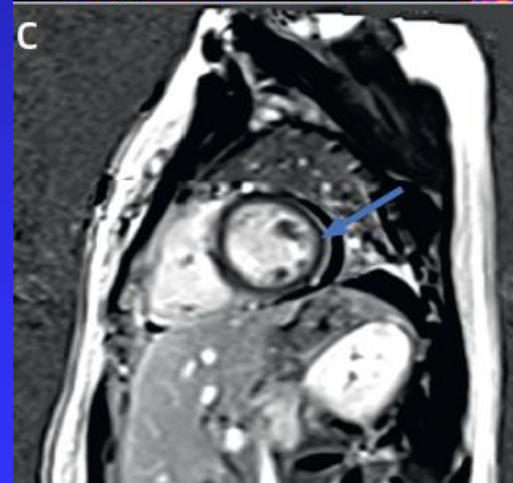
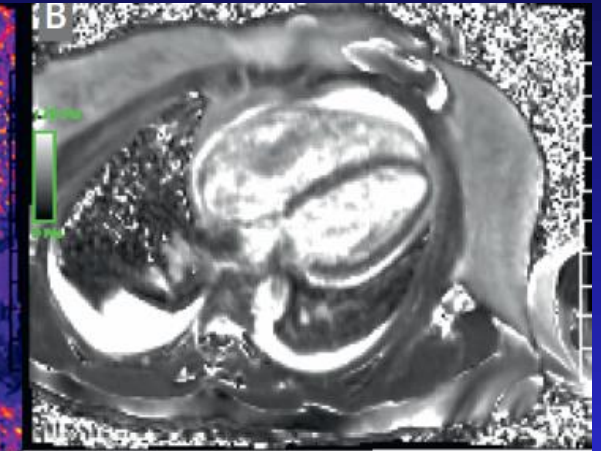
## Pericarditis:

- Pericardialis folyadék
- Megvastagodás  $3\text{ mm} <$
- Szignál intenzitás LGE, T1, T2
- Mozgás, kitapadás

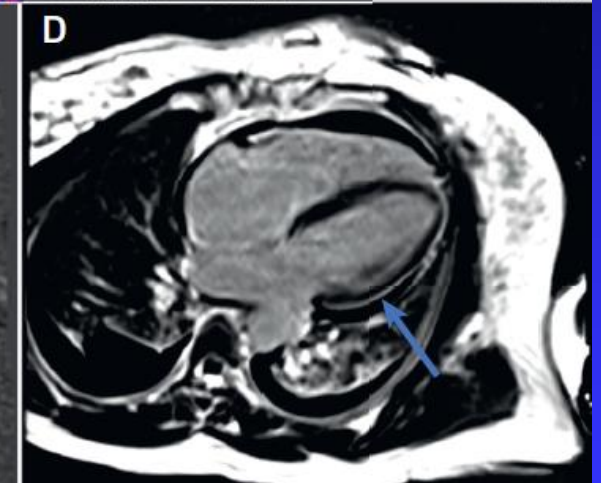
T1 mapping



T2 mapping



LGE rövid tengely

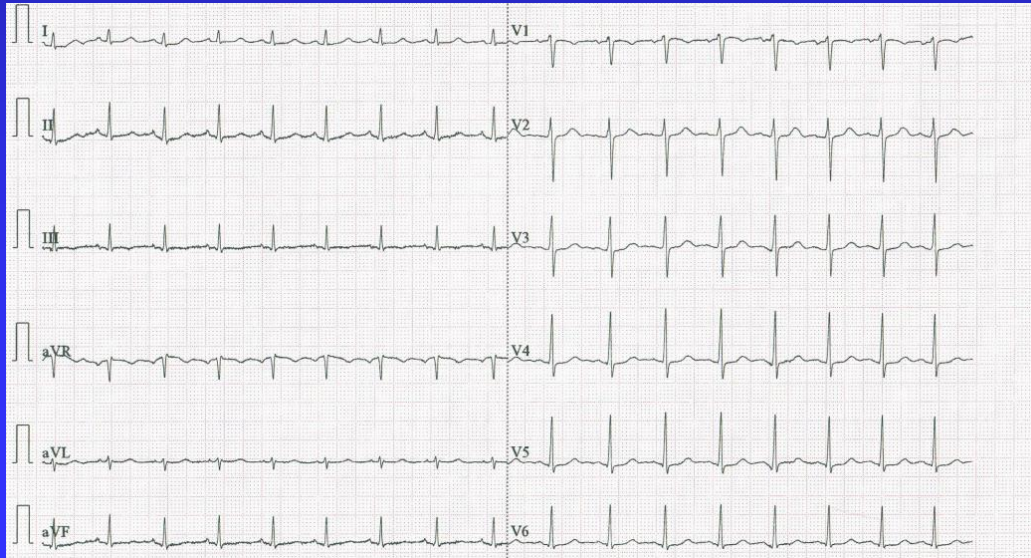


LGE hossz tengely



# Esetismertetés

- 37 éves nőbeteg, Post-Covid/Long-Covid szindróma
- Perzisztáló panaszok
- Ismételt negatív ambuláns vizsgálatok
  - Labor
  - Nyugalmi EKG
  - Holter EKG
  - Echocardiographia

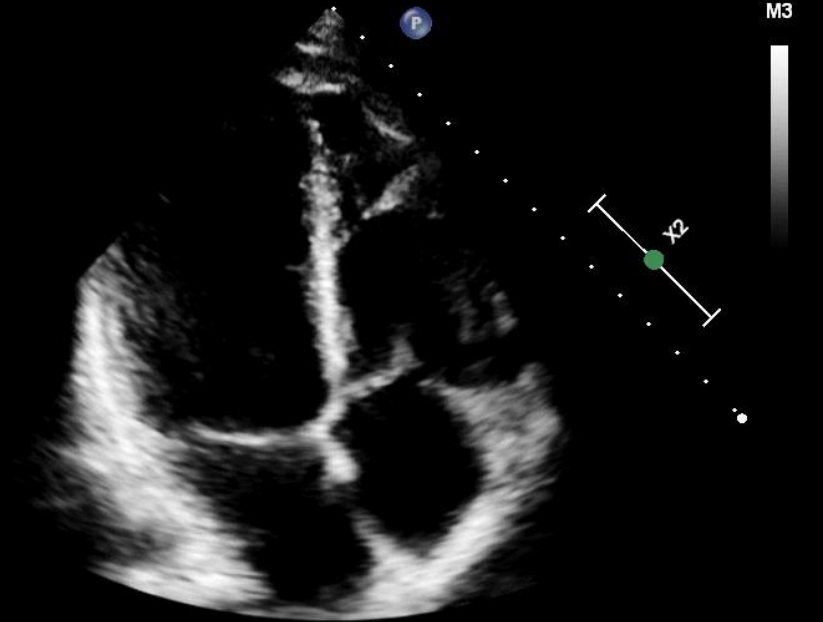

Adult Echo

S6-1  
51Hz  
15cm

2D  
67%  
C 50  
P Low  
HGen

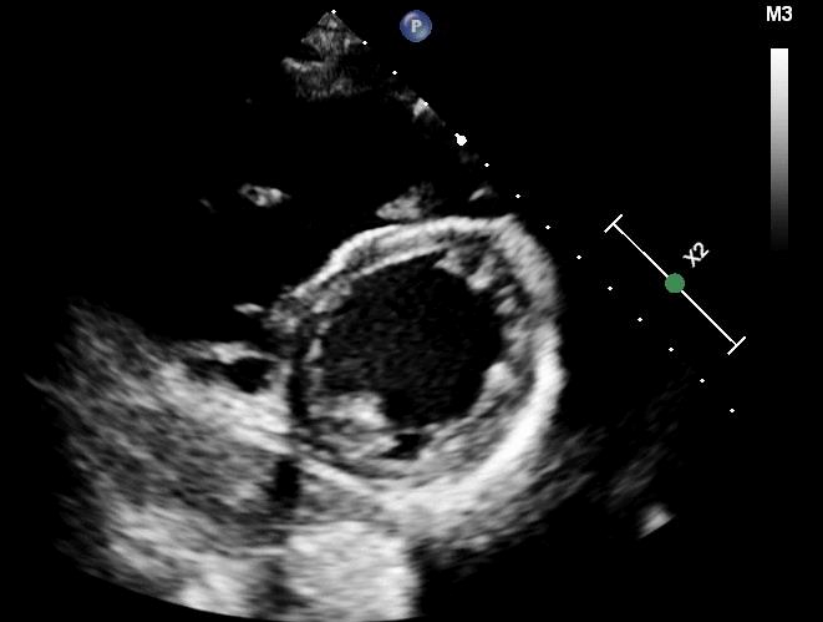
G  
P R  
1.6 3.2



53Hz  
14cm

2D  
67%  
C 50  
P Low  
HGen

G  
P R  
1.6 3.2

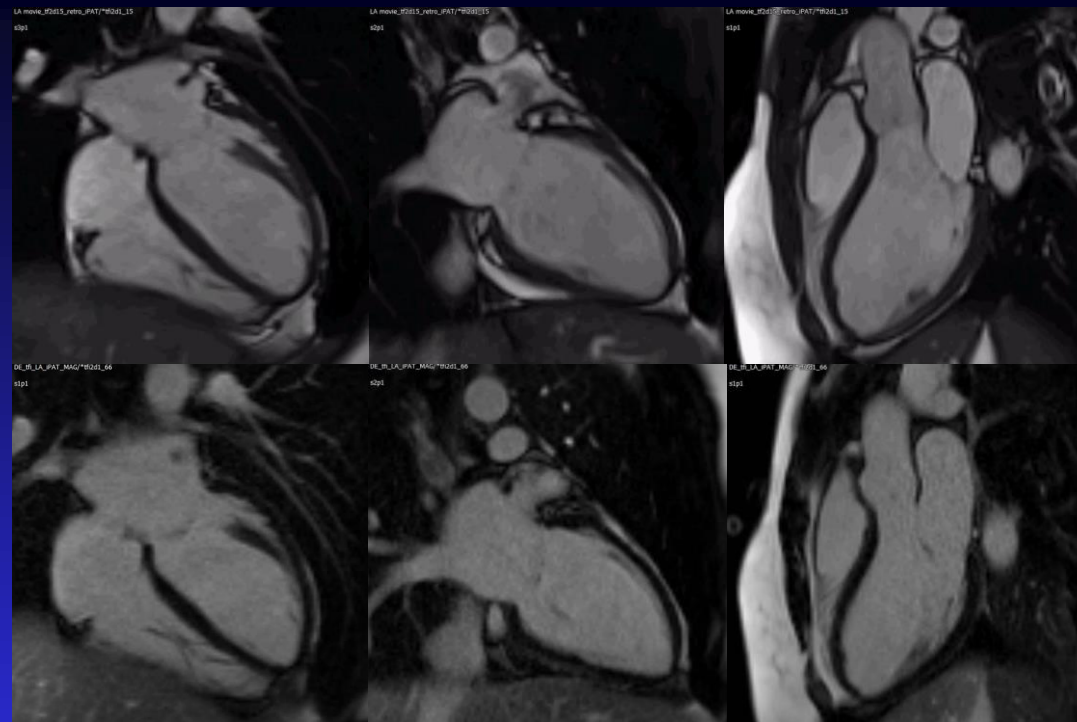




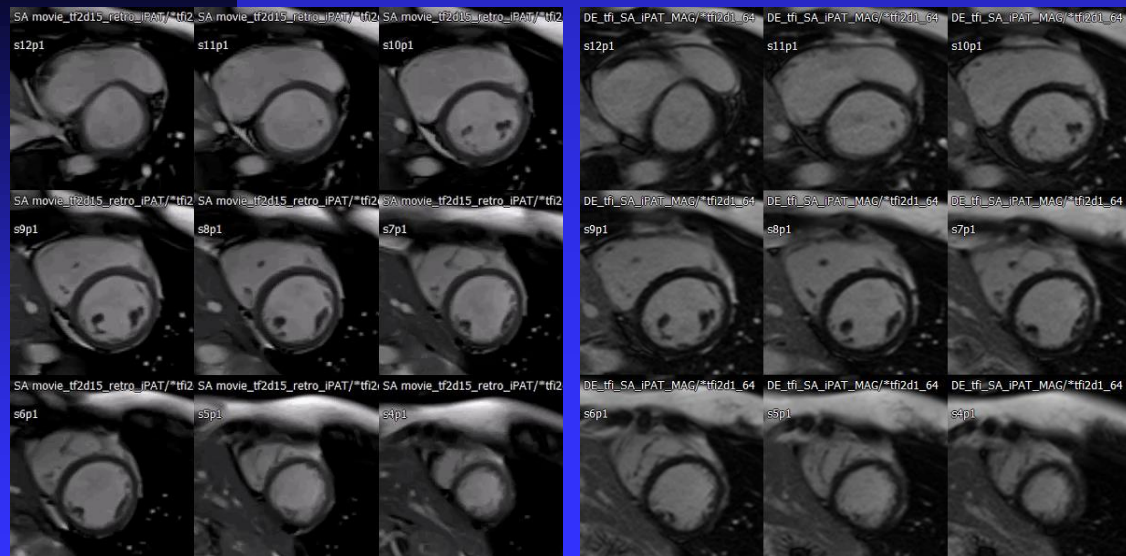
# Szív MRI vizsgálat

## Peri- myocarditis

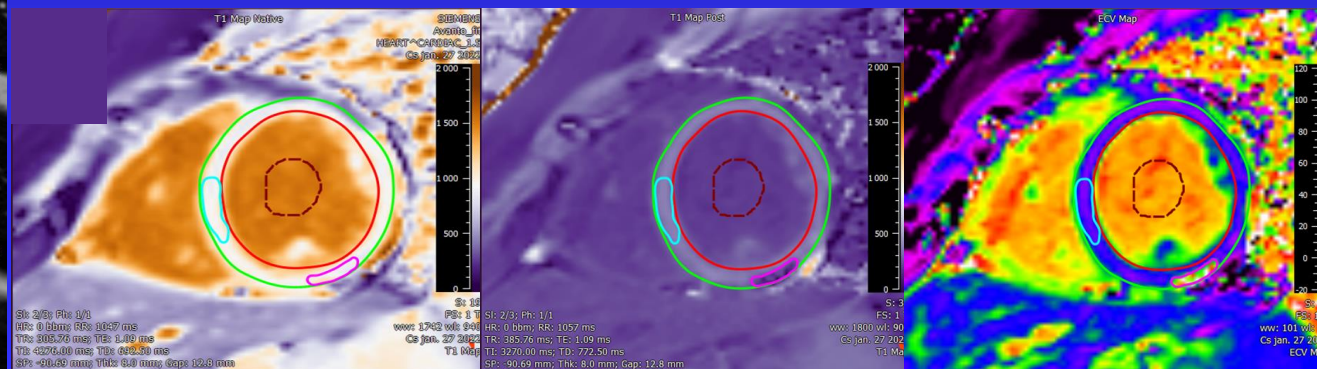
- ❑ Konvencionális MR képeken: jó funkció, normál volumenek, LGE nincs
- ❑ A perikardium kitapadása a bal kamra inferior fala mentén
- ❑ T1 mapping és ECV: foltos szubepikardiális eltérések
- ❑ A látott kép lezajlott peri-myocarditisnek felel meg



Hossztengely movie és LGE felvételek



Rövidtengely movie és LGE felvételek

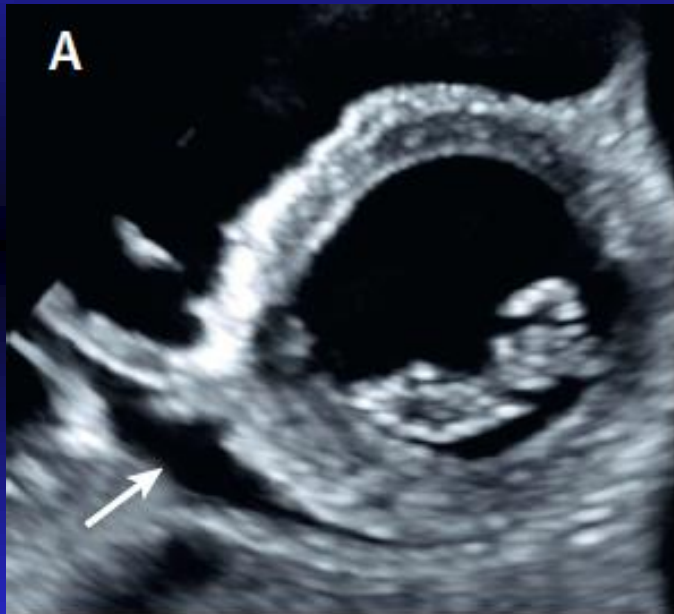


Pre-kontraszt T1, post-kontraszt T1 és ECV felvételek

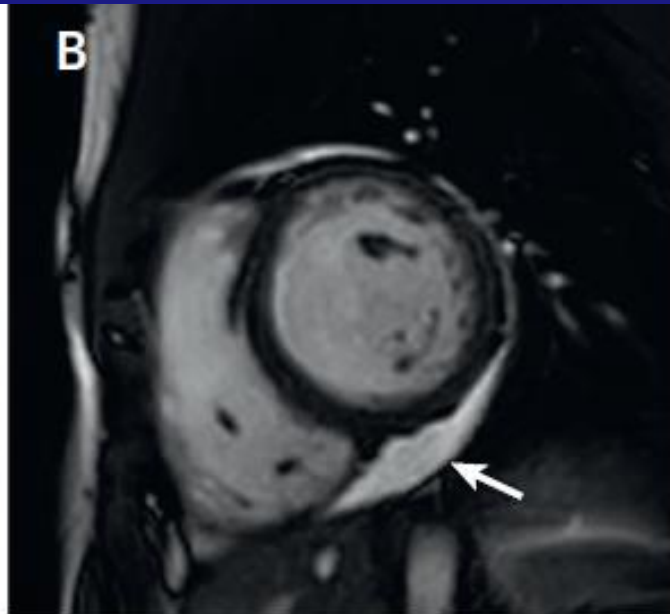


# Pericardialis folyadék echo és MRI diagnosztikája

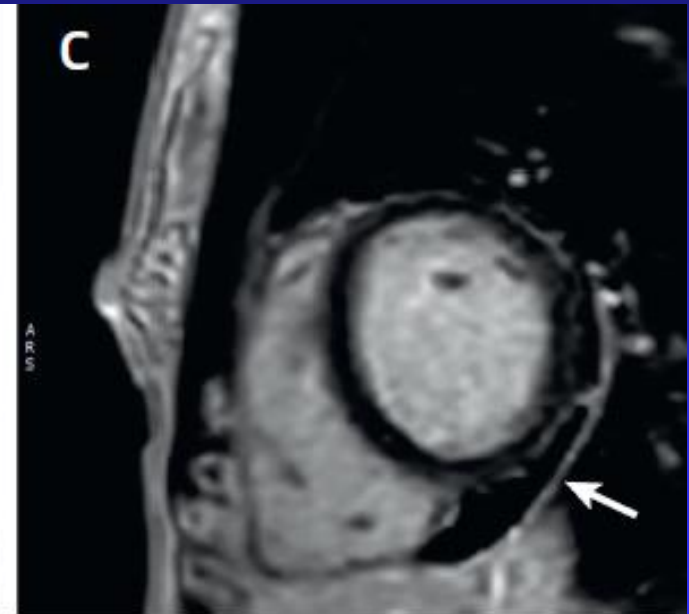
Echocardiographia



CMR movie



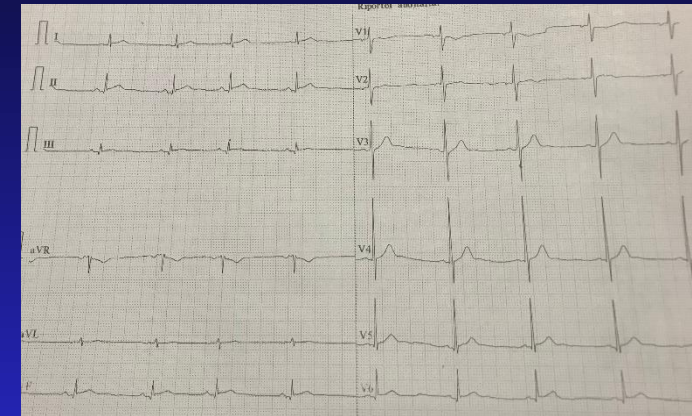
CMR LGE



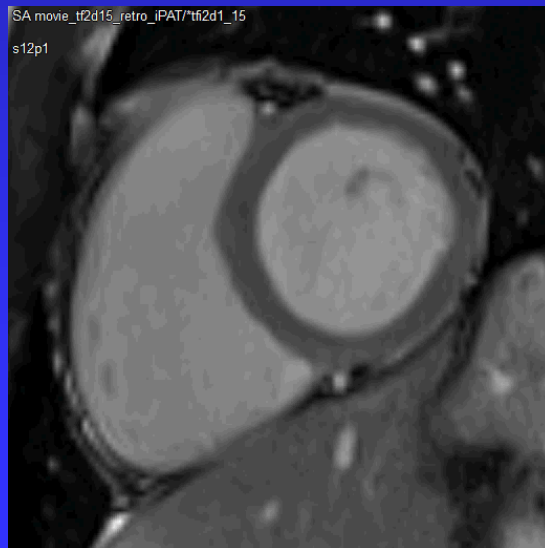

# Post-Covid pericarditis - Esetismertetés

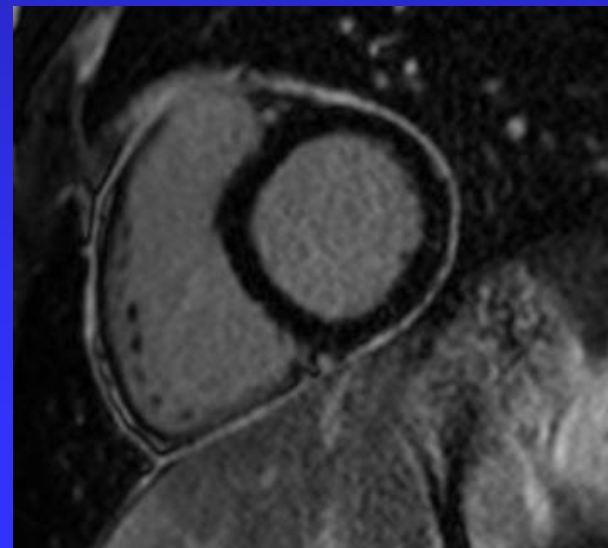
- 31 éves férfi
- Mellkasi panaszok
- Nyugalmi EKG-n ST elevatio
- Mérsékelt troponin emelkedés – negatív coronarographia



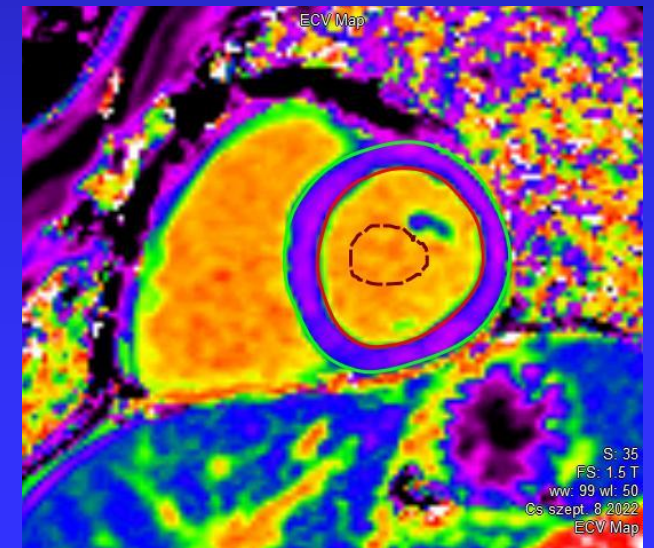
CMR movie



CMR LGE



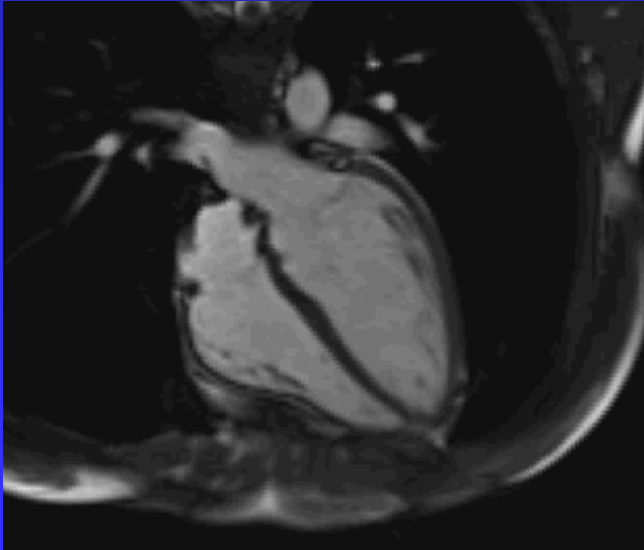
CMR ECV



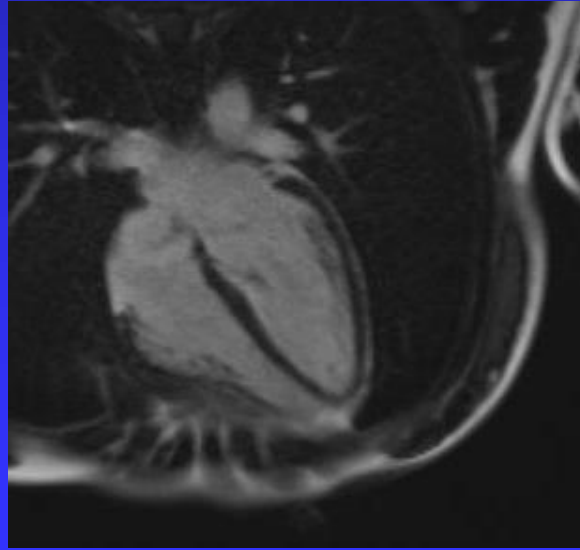
# Myocarditis - Esetismertetés

- 41 éves nő
- Atípusos mellkasi panaszok
- Nyugalmi EKG, Holter EKG negatív
- Labor eredmény eltérés nélkül, perzisztáló panaszok
- Natív T1 1180 ms, ECV 35 %


CMR movie



CMR LGE



CMR ECV





# Kardiomiopátiák

63 éves nő

ED: 95.18 ml,  
20.95 ml

SV: 74.22 ml,  
4304.96 ml

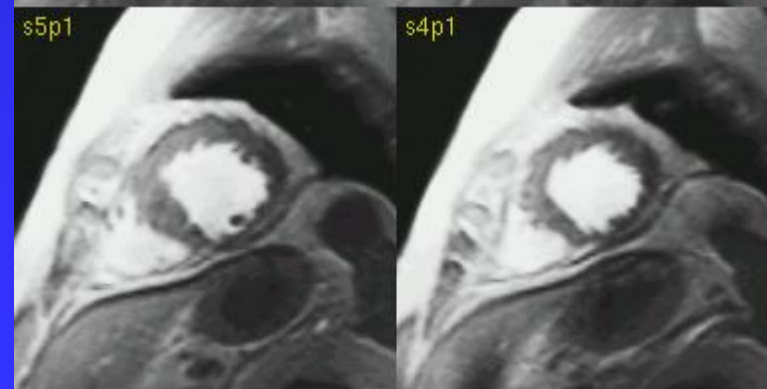
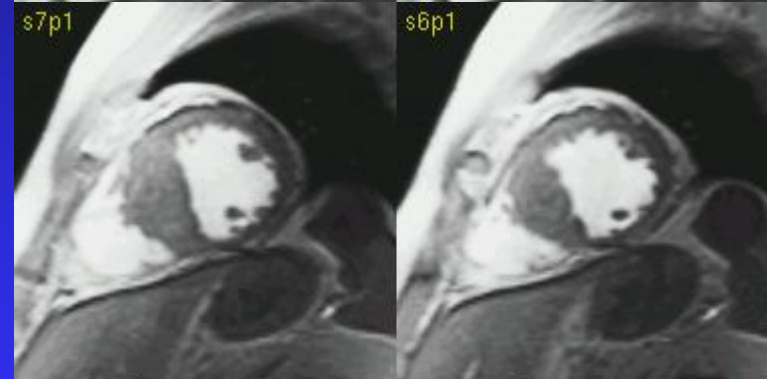
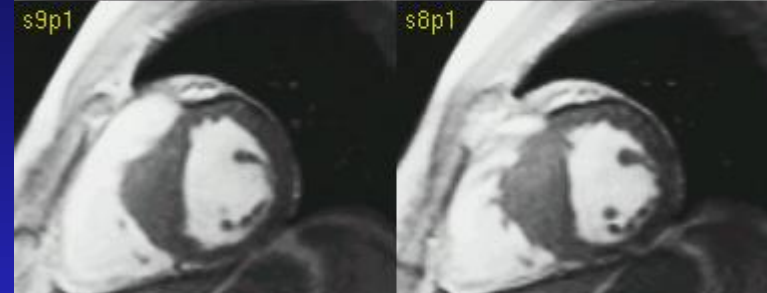
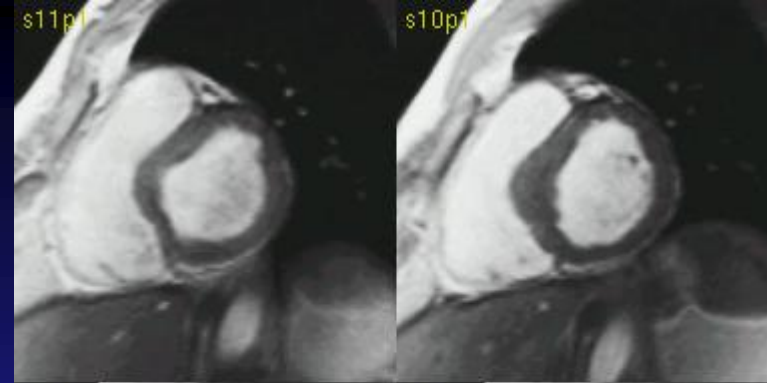
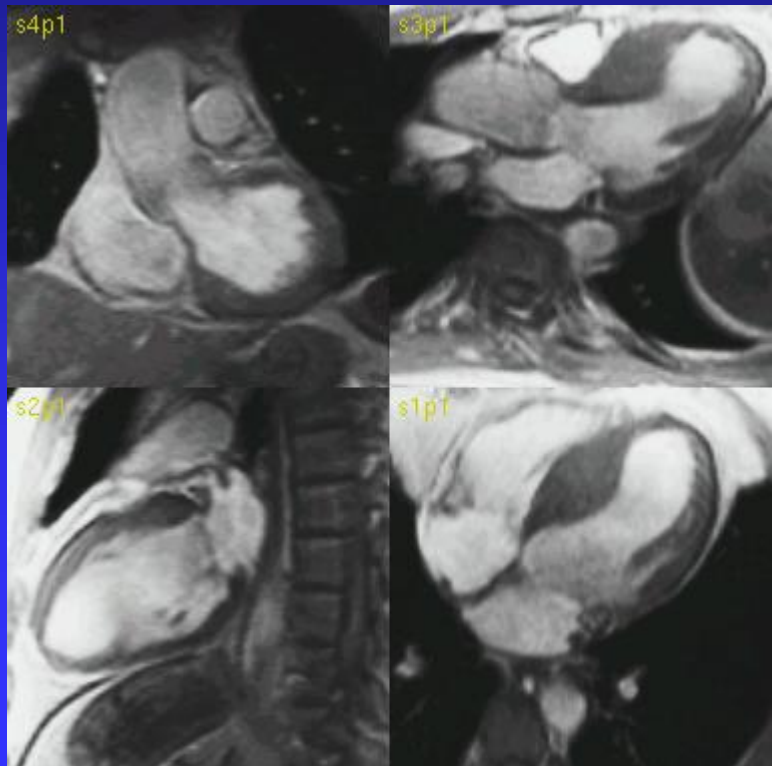
EF: 77.99 %

MASS: 92.51 g

ES:

CO:

PFR: 207 ml/sec





# 2023 ESC Guidelines for the management of cardiomyopathies

Cardiomyopathy phenotype	Finding	Cardiac CMR examples	Specific diseases to be considered
HCM	Posterolateral LGE and concentric LVH Low native T1		Anderson–Fabry disease
	Diffuse subendocardial LGE, high native T1		Amyloidosis
	Patchy mid-wall in hypertrophied areas		Sarcomeric HCM
DCM	Short T2*		Haemochromatosis
	Subepicardial LGE		Post-myocarditis
	Lateral wall epicardial LGE		Dystrophinopathy
	Subepicardial and midwall LGE at basal septum +/- extension into inferolateral wall and RV insertion points		Sarcoidosis
	Apical transmural LGE		Chagas disease

NDLVC	Ring-like and/or subepicardial LGE pattern		DSP variants FLNC variants DES variants
	Septal mid-wall LGE		Laminopathy
ARVC	Fat and LGE (transmural RV plus sub-epicardial-midmural LV free wall)		Desmosomal variants
RCM	Partial LV or RV apical obliteration + LGE at endocardial level		EMF/hypereosinophilia

Recommendations	Class <sup>a</sup>	Level <sup>b</sup>
Contrast-enhanced CMR is recommended in patients with cardiomyopathy at initial evaluation. <sup>10,90,116,119–143</sup>	<b>I</b>	<b>B</b>



ESC

European Society  
of Cardiology

European Heart Journal (2022) 43, 3997–4126  
<https://doi.org/10.1093/eurheartj/ehac262>

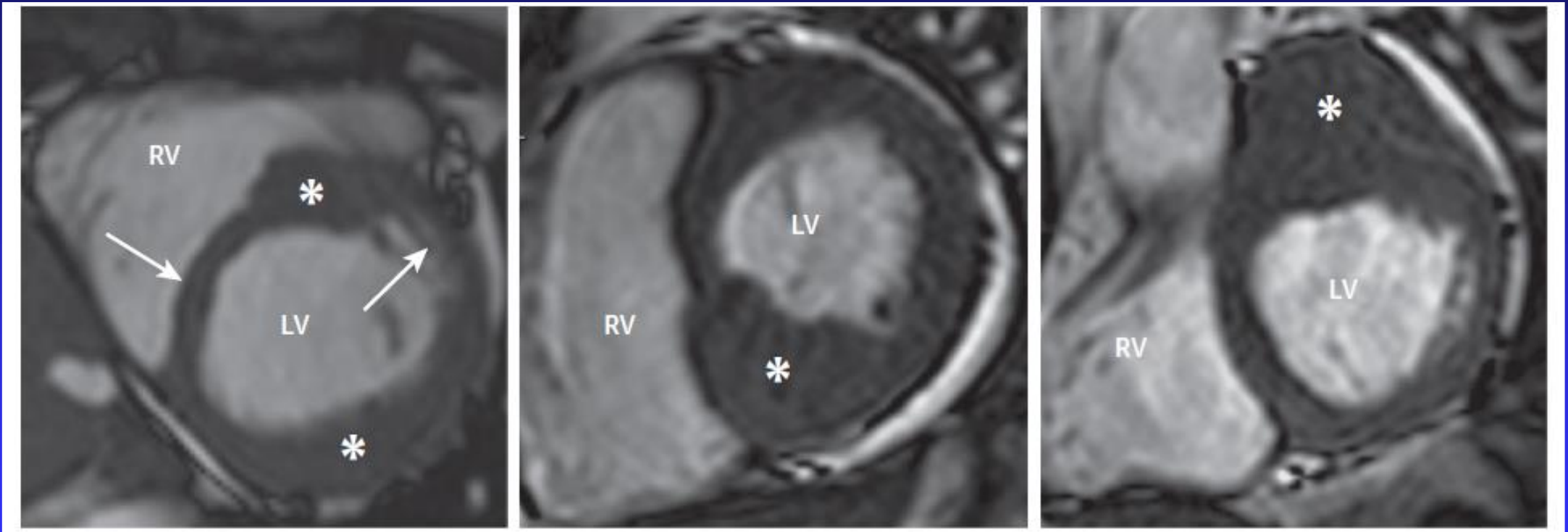
ESC GUIDELINES

## 2022 ESC Guidelines for the management of patients with ventricular arrhythmias and the prevention of sudden cardiac death

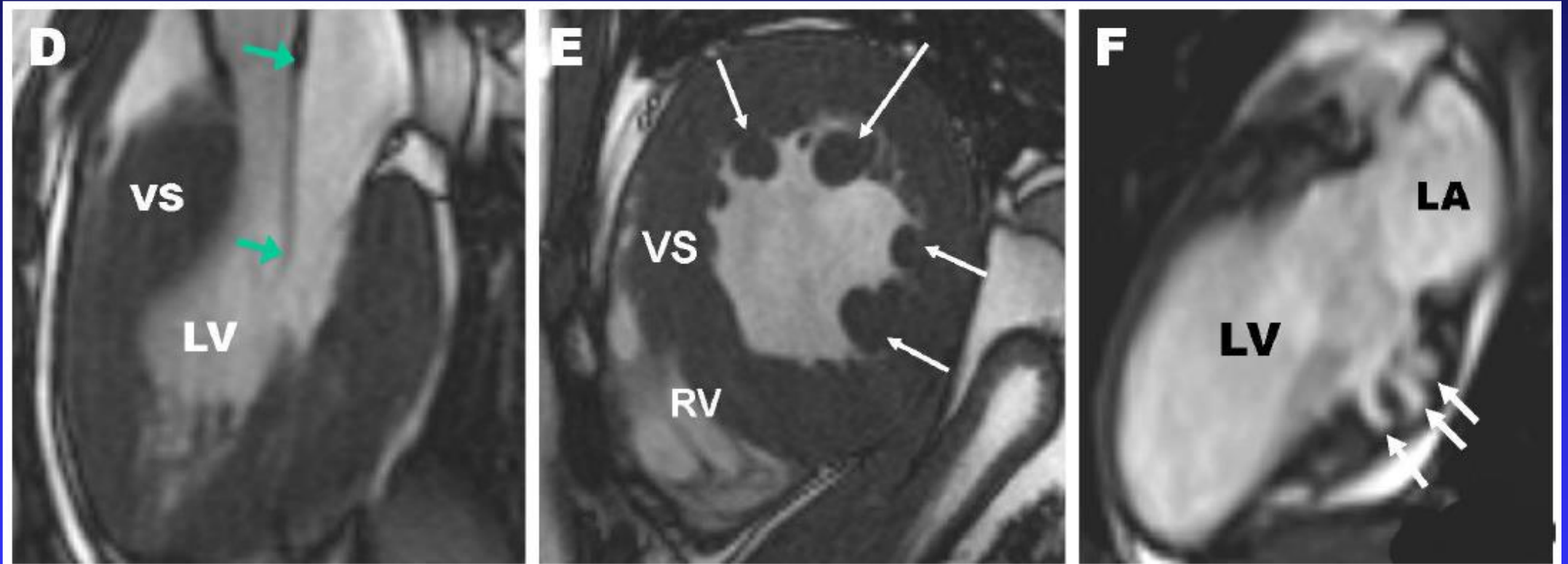
ARVC	
In patients with suspected ARVC, CMR is recommended.	I
In patients with a suspected or definite diagnosis of ARVC, genetic counselling and testing are recommended.	I
ICD implantation should be considered in symptomatic <sup>d</sup> patients with definite ARVC, moderate right or left ventricular dysfunction, and either NSVT or inducibility of SMVT at PES.	IIa
In ARVC patients with indication for ICDs, a device with the capability of ATP programming for SMVT up to high rates should be considered.	IIa
Avoidance of high-intensity <sup>e</sup> exercise may be considered in carriers of ARVC-related pathogenic mutations and no phenotype.	IIb
Beta-blocker therapy may be considered in all patients with a definite diagnosis of ARVC.	IIb
In patients with ARVC and symptoms highly suspicious for VA, PES may be considered for risk stratification.	IIb
HCM	
CMR with LGE is recommended in HCM patients for diagnostic work-up.	I



# HCM

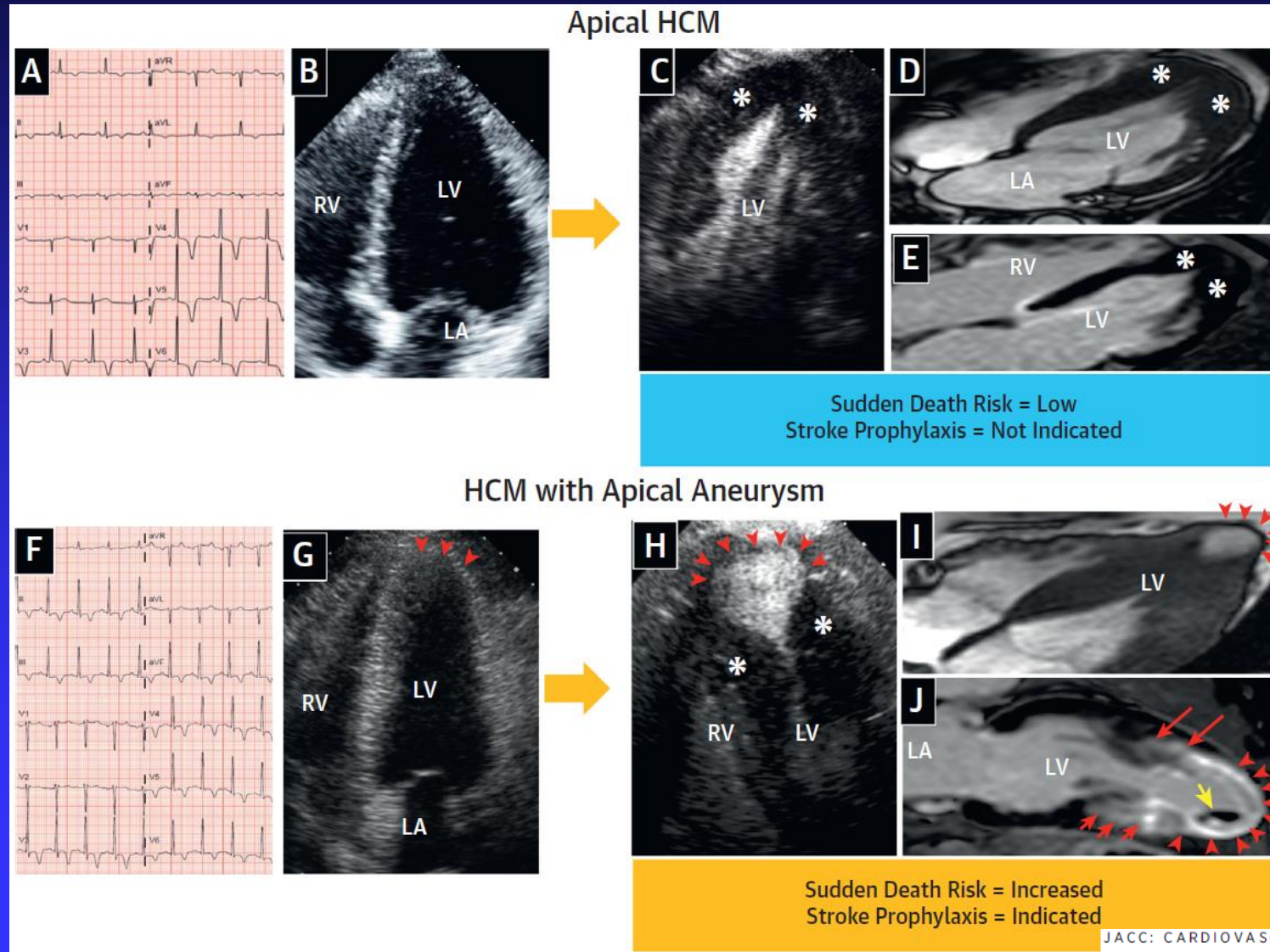


# HCM fenokópiák II.



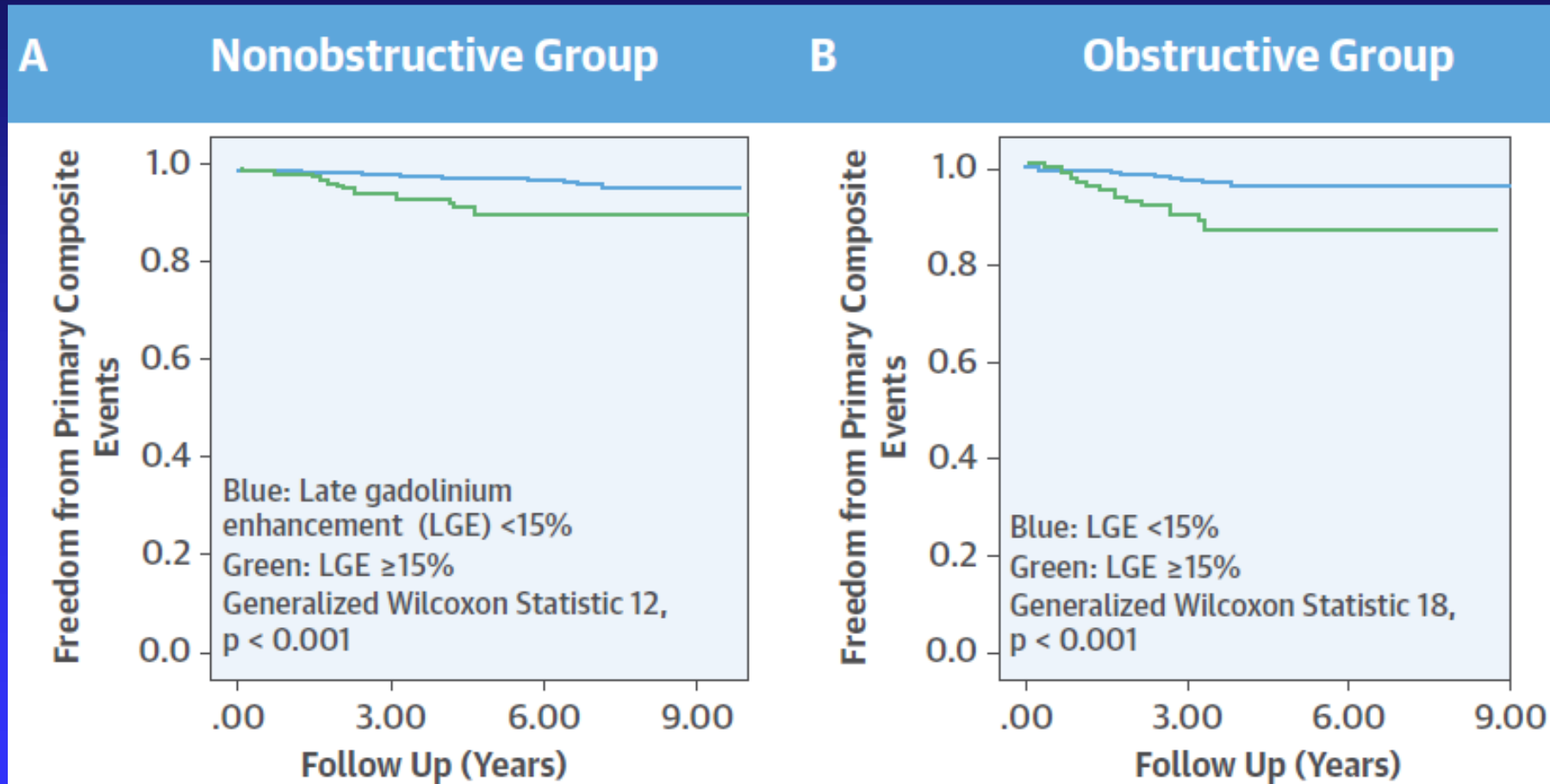


# HCM fenokópia és terápiás algoritmus



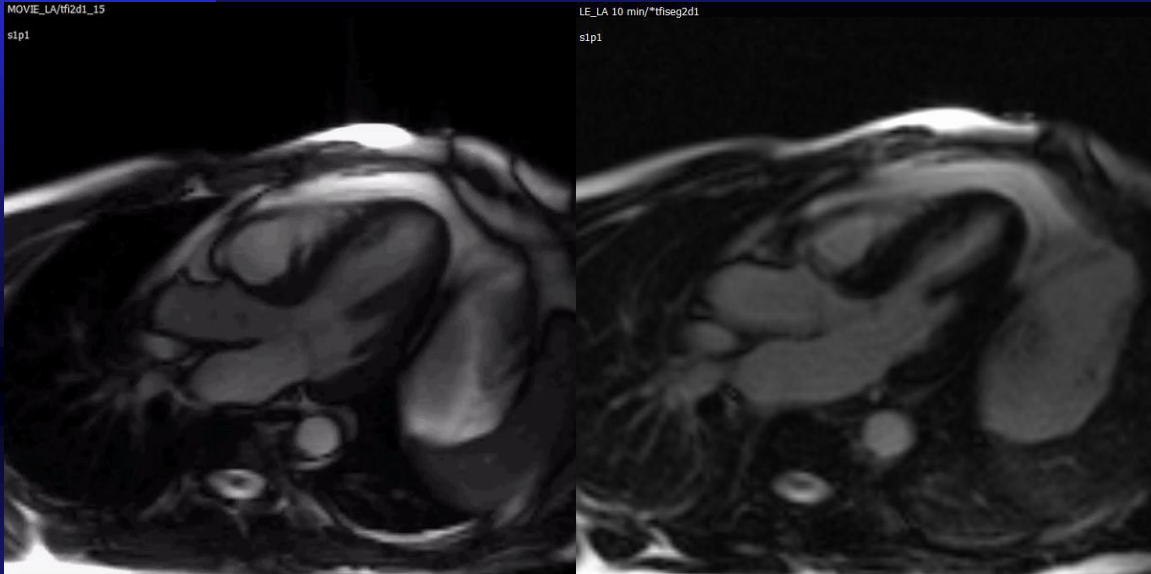


# MRI LGE prediktív szerepe az SCD rizikóra

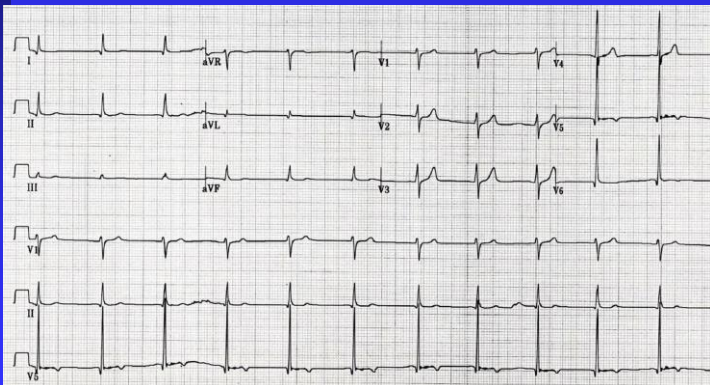


# Fabry beteg utánkövetése

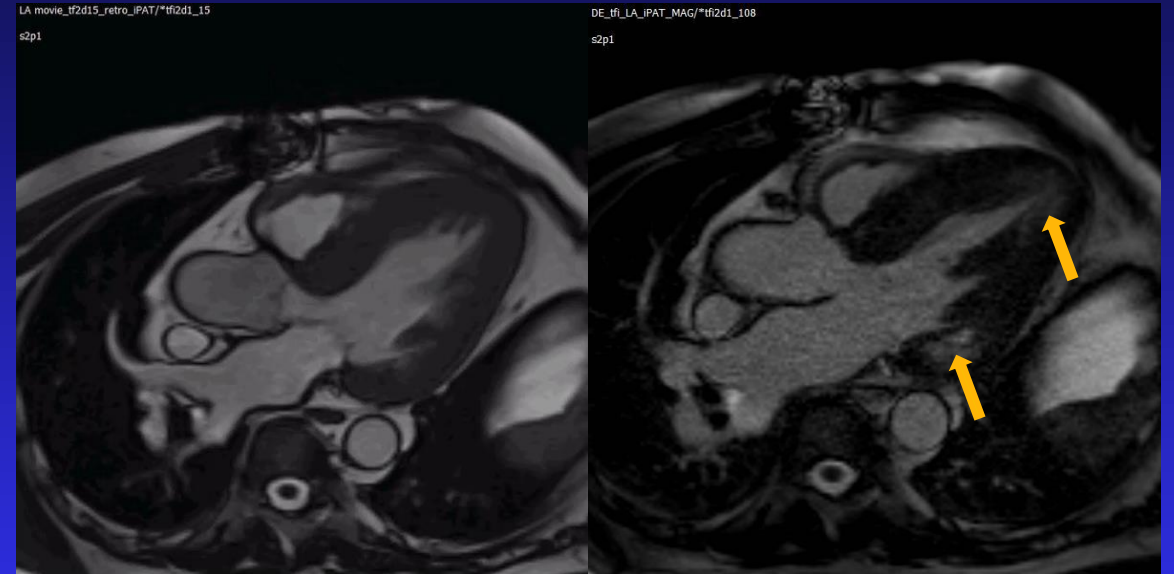
2007



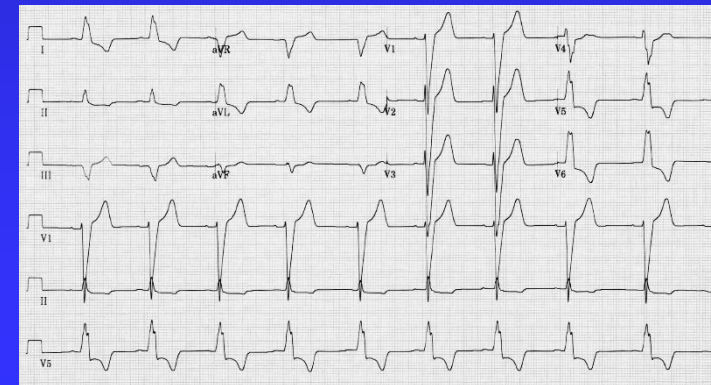
2007: Left ventricular outflow tract cine and LGE image



2019



2019: Left ventricular outflow tract cine and LGE image



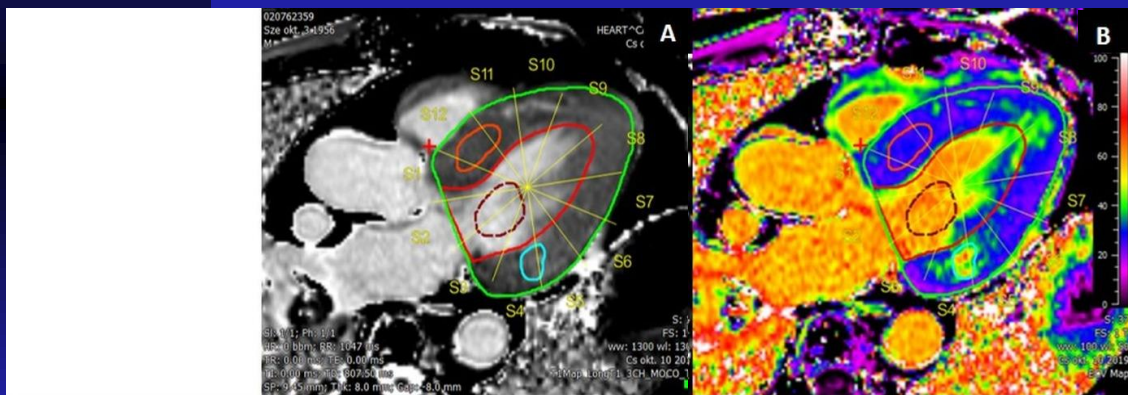
# Új MRI modalitások, korai célszerv károsodás kimutatása

## T1 mapping, ECV

## Feature tracking

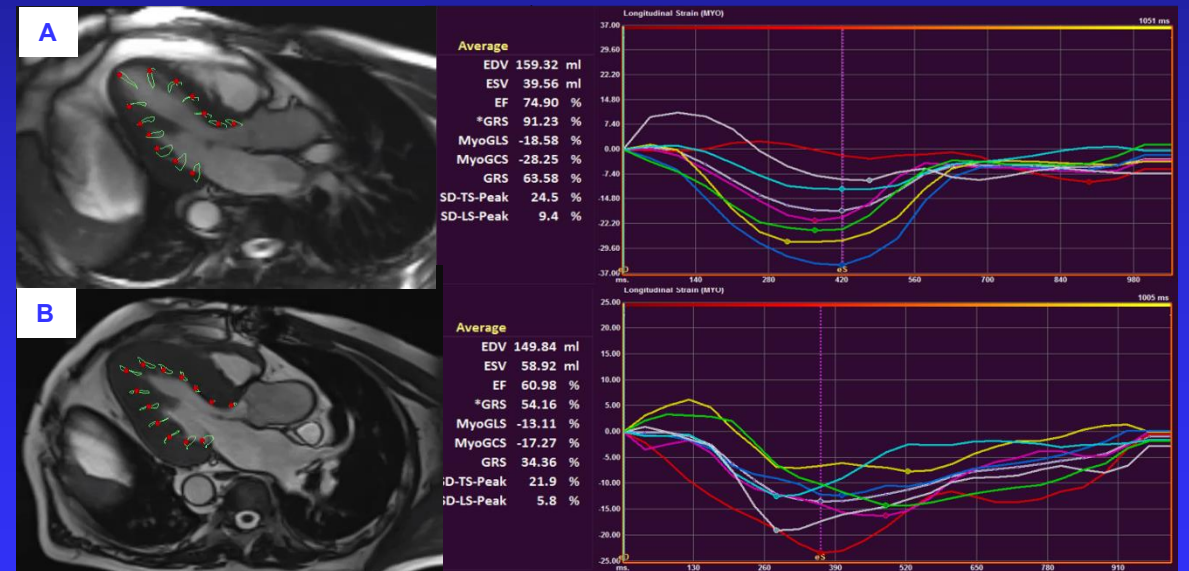
- Normal native T1 value due to the advanced, fibrotic stage of the disease
- Locally increased ECV
- Normal global myocardial ECV

- Global and segmental strain reduction at the late stage of the disease.
- Postprocessing the baseline CMR images at age of 50-years, segmental strain reduction



	Native T1 (ms)	ECV (%)
Myocardium	1045	31,1
Blood pool	1648	59,4
Inferolateral basis	1136	47,6
Anteroseptal basis	990	27,5

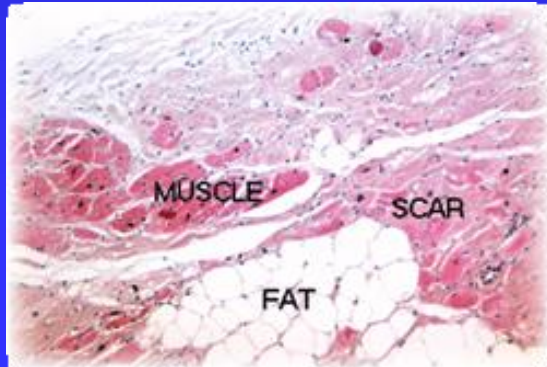
Native T1 (A) and ECV images (B) at age 64 years



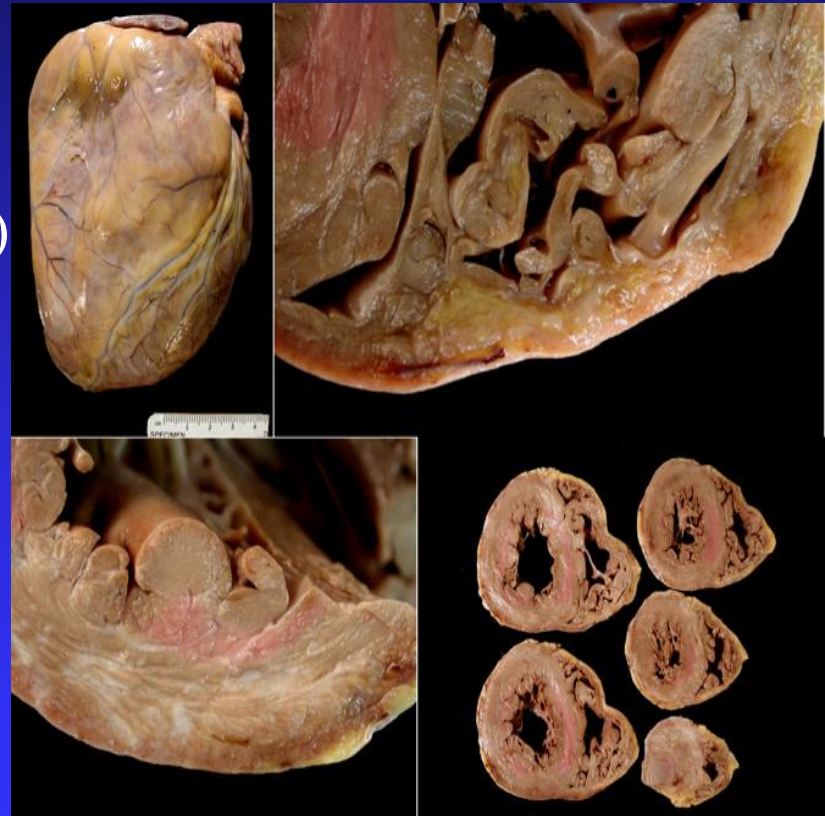Myocardial strain by feature tracking (QStrain 2.0) at baseline (A) and at age of 64 years (B)

# AC patofiziológia

- ❑ Fiatalkori hirtelen szívhalál! (~20 %)
- ❑ Prevalencia 1/5000
- ❑ Autoszomális domináns
- ❑ Dezmoszóma fehérje génmutáció
- ❑ Progresszív, degeneratív (~ 40 év)
- ❑ Zsíros - kötőszövetes elfajulás
- ❑ Végeredmény: myocard.  
vesztés – szívelégtelenség +  
kamrai ritmuszavar (BTSZB)



Pathology of an ARVD/C Heart



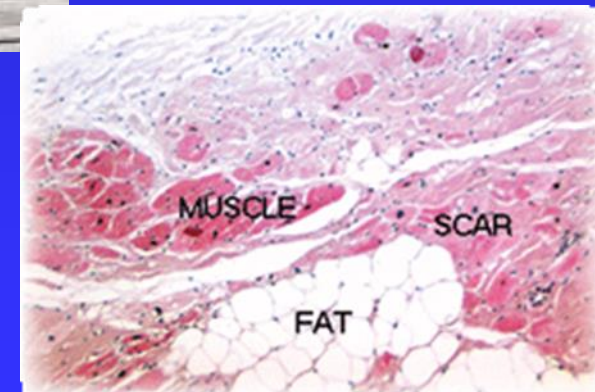


# AC diagnózis: Task Force 2010

- EKG: Depolarizáció  
Repolarizáció
- Jobb kamrai falmozgászavar  
Tág jobb kamra, csökkent EF
- Ritmuszavar (BTSZB VT, syncope)
- Családi halmozódás, genetika
- Szövettan (biopszia - ritka, autopszia)
  
- Major és minor kritériumok alapján



# Világbajnok halála (3 major kritérium)



Pathology of an ARVD/C Heart



ESC

European Society  
of Cardiology

European Heart Journal (2021) 42, 17–96

doi:10.1093/eurheartj/ehaa605

ESC GUIDELINES

## 2020 ESC Guidelines on sports cardiology and exercise in patients with cardiovascular disease

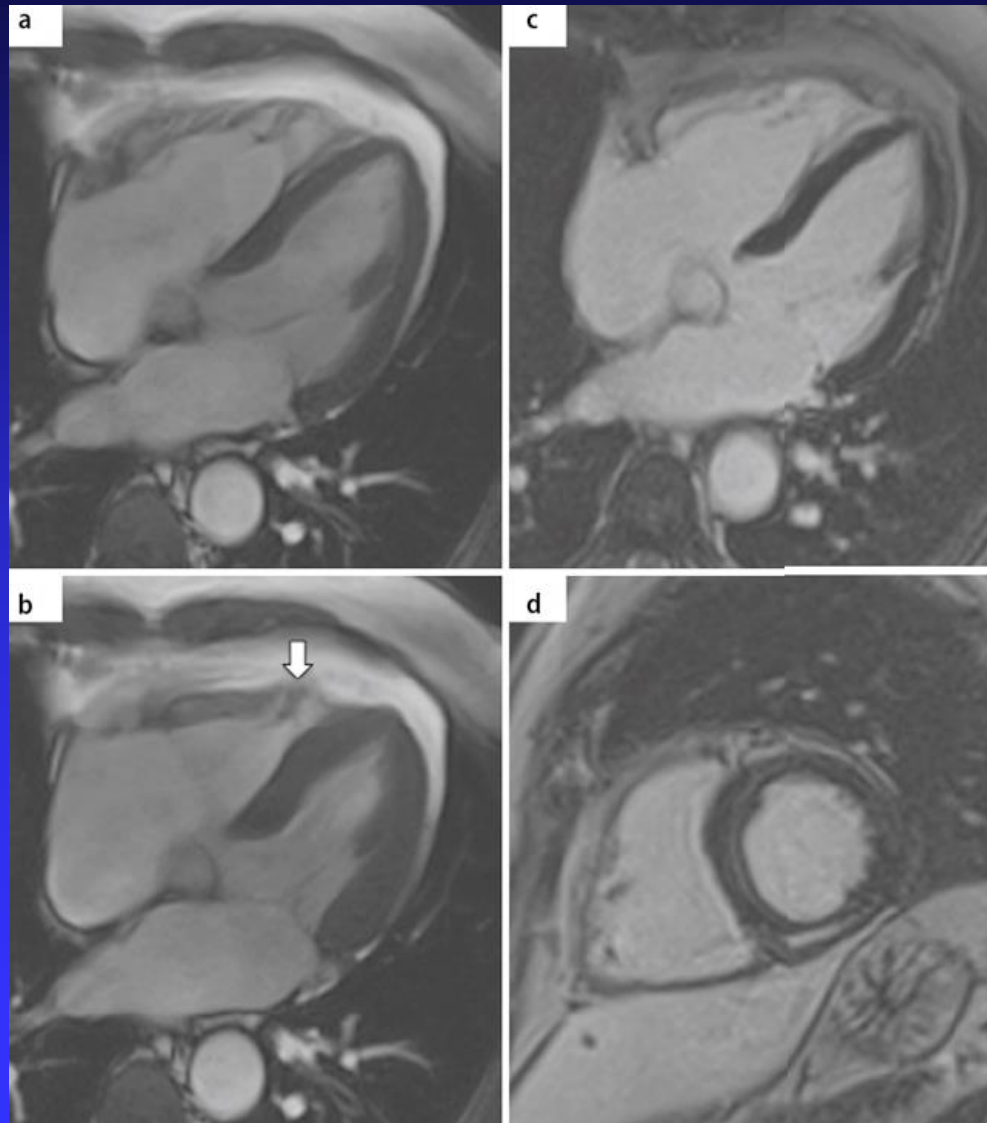
The Task Force on sports cardiology and exercise in patients with cardiovascular disease of the European Society of Cardiology (ESC)

Participation in high-intensity recreational exercise/  
sports or any competitive sports is not recom-  
mended in individuals with ACM, including those  
who are gene positive but phenotype negative.<sup>384,386</sup>

III

B

## ARVD helyett AC: Aritmogén kardiomiopátia

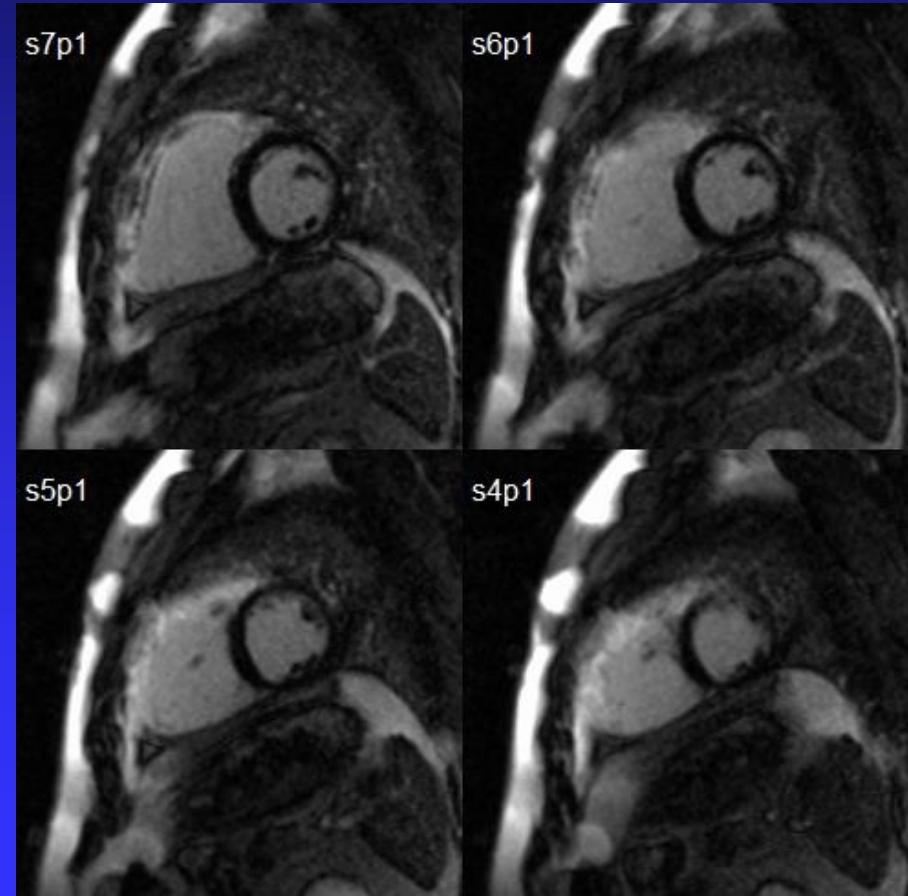
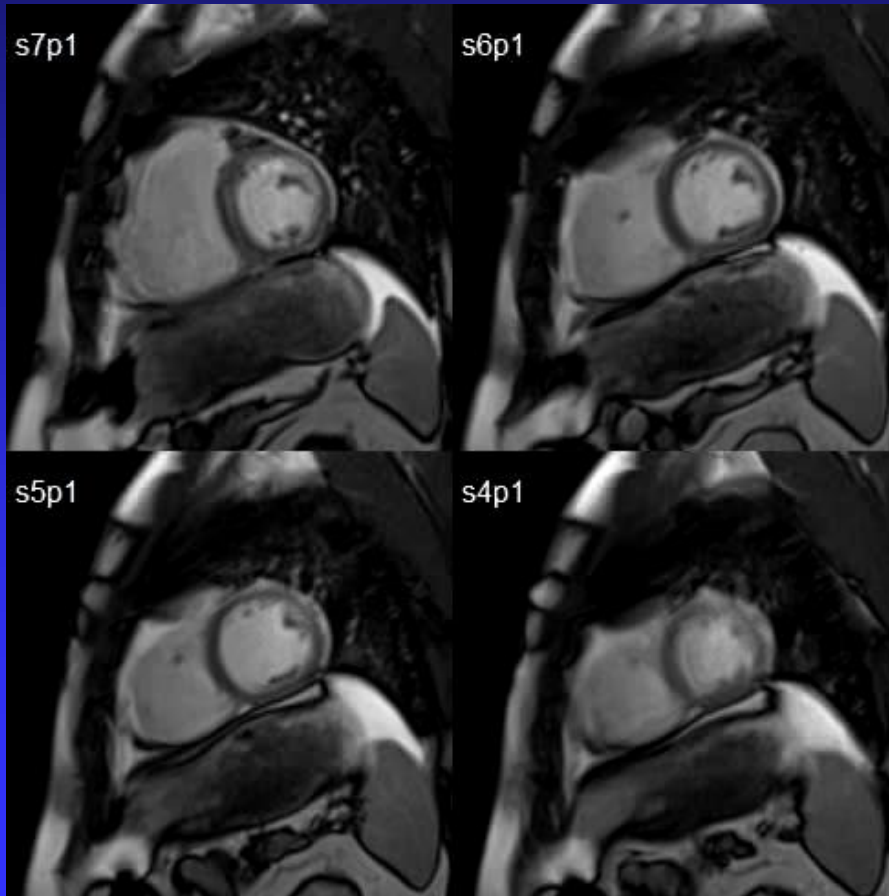


Subepicardialis,  
midmyocardialis

ARVD bal domináns  
formája???



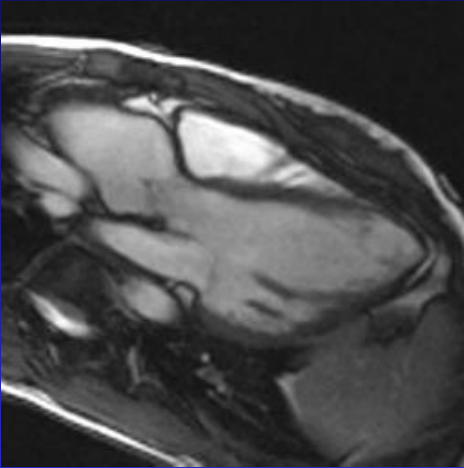
## AC (ARVD)



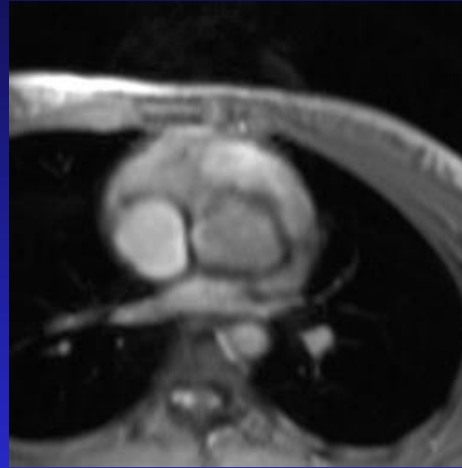


# MRI: bal kamra funkció, morfológia, áramlás mérés

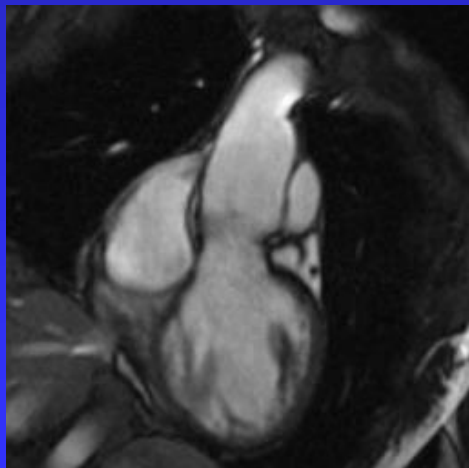
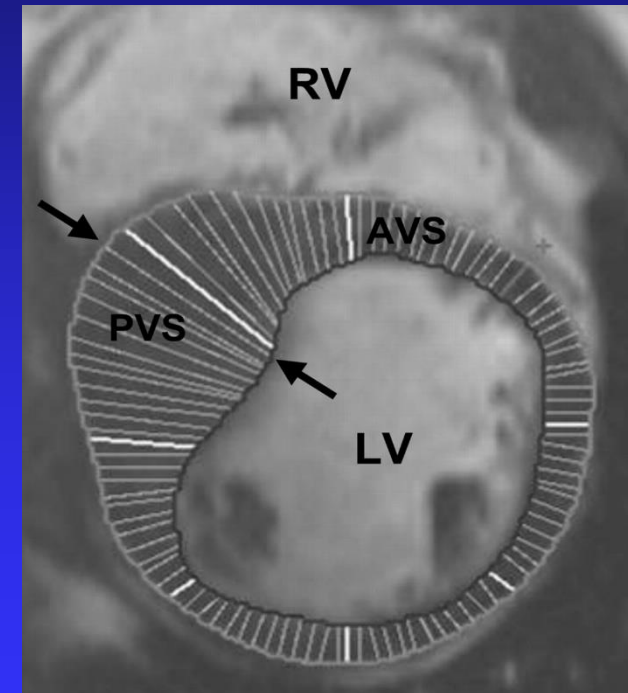
**LVOT cine**



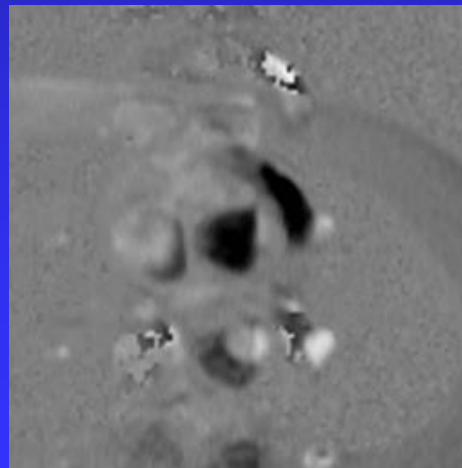
**Aorta cine**



**Szegmentum átmérő**



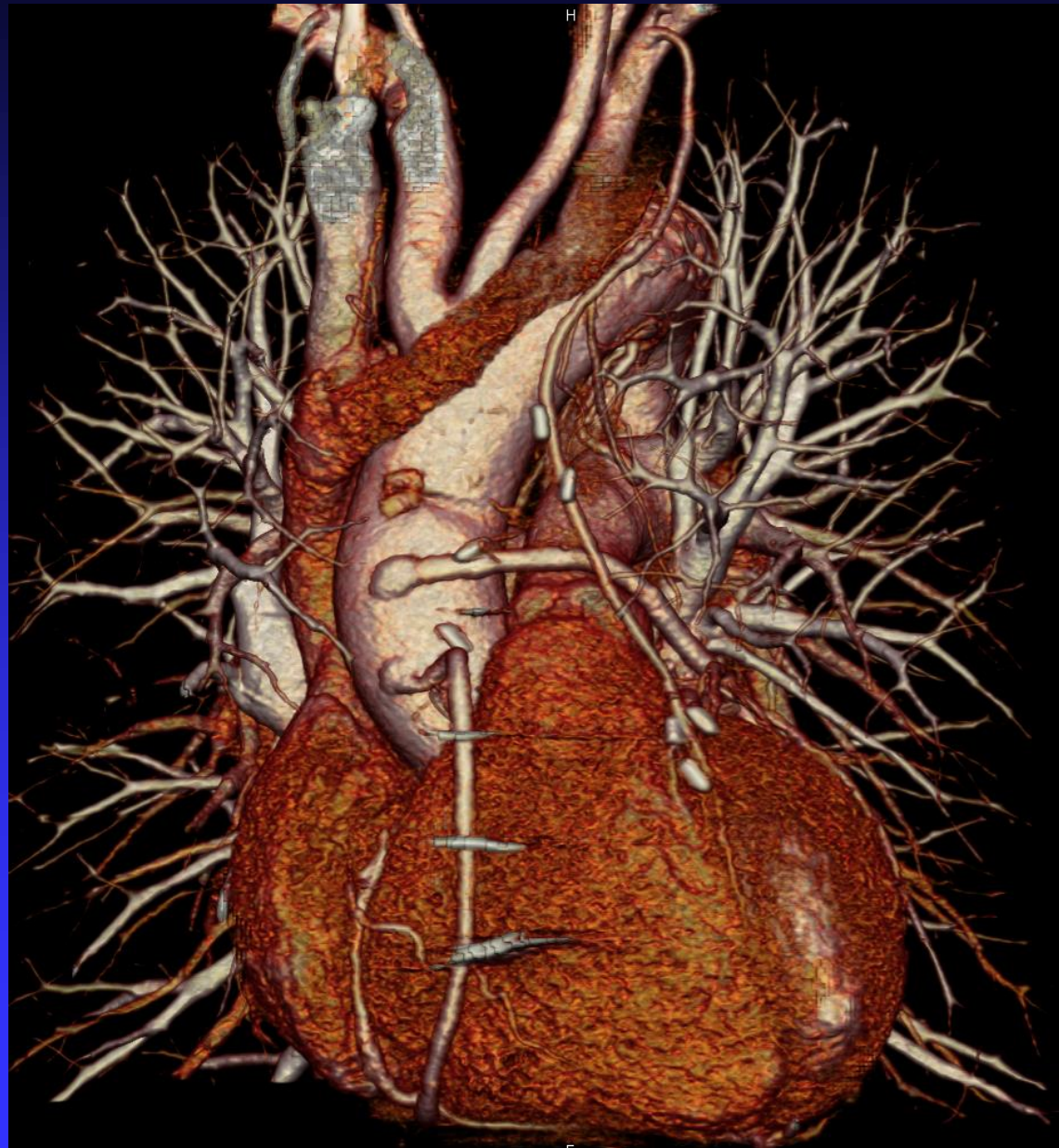
**LVOT perpendic cine**



**Aorta flow - cine**

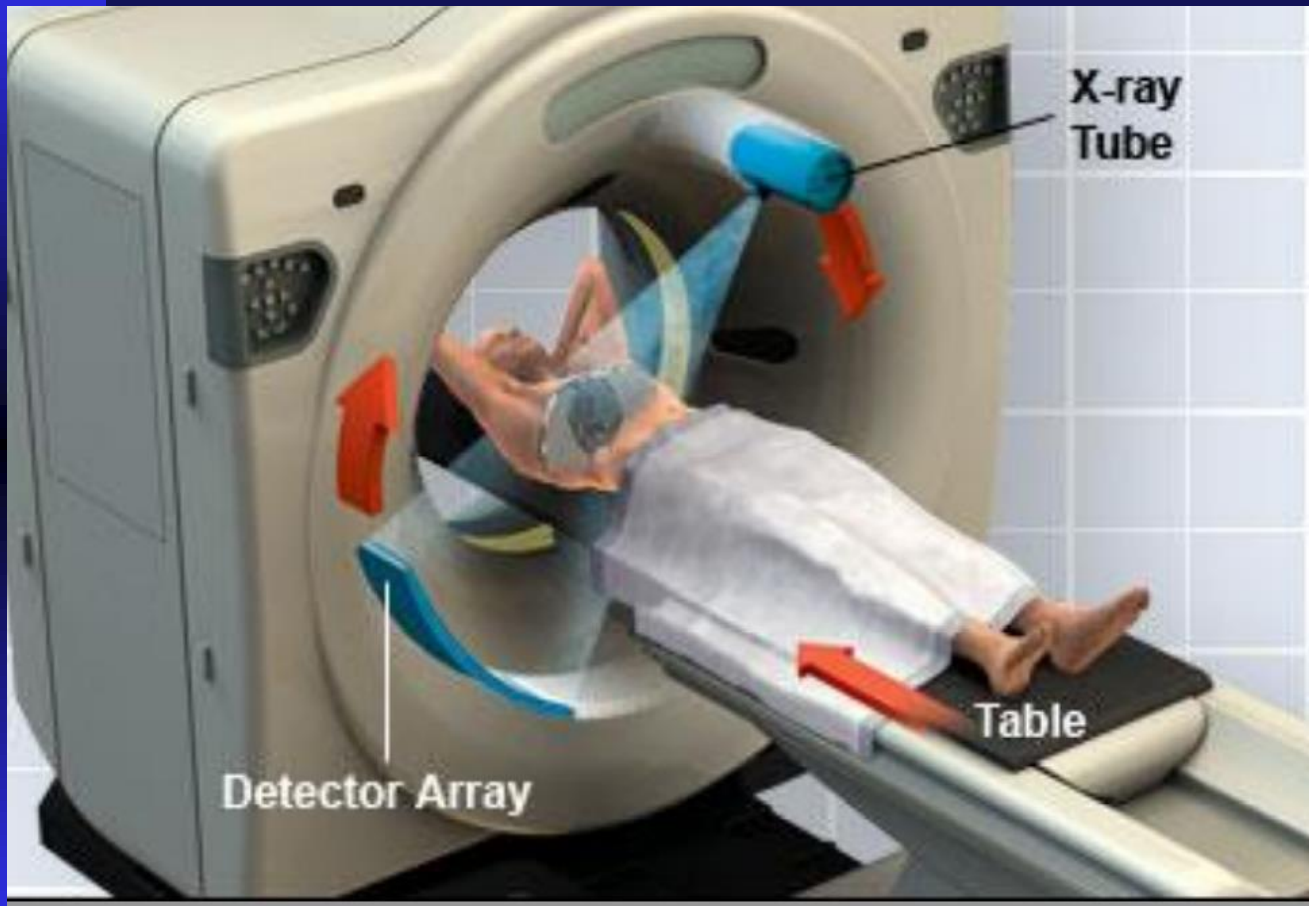


# Coronaria CT

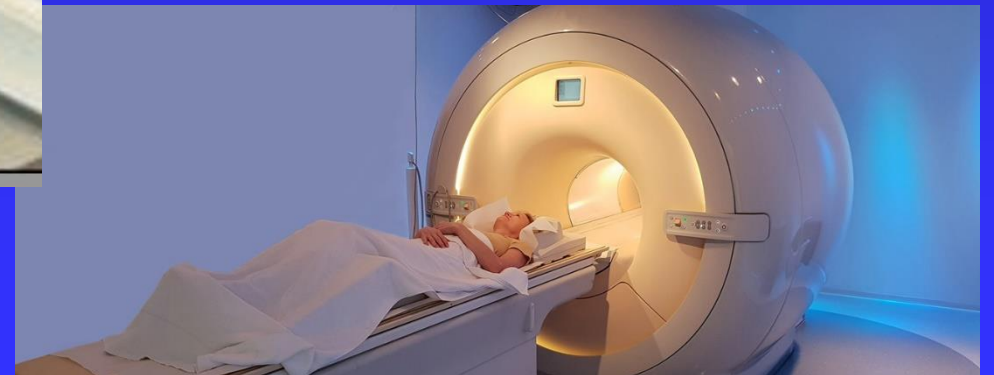



# Coronaria CT



- Non-invazív
- Gyors (5-15 sec)
- Pontos (térbeli felbontás  $<0.4$  mm)
- Sugárzás (Rtg)





# Natív MSCT indikáció

- Calcium scoring (AHA guideline)
- Panaszos betegek (SBO)
  - Mellkasi fájdalom differenciál diagnózisa („triple rule out”)
  - No Ca = no CAD (95% NPV)
  - Alacsony – közepes CV rizikó (kontraszt MSCT)
- Panaszmentes betegek
  - magas CV rizikó (coronarographia)
  - Ca emelkedés = rizikó faktor
- Klinikai vizsgálatok
  - Koleszterin csökkentő gyógyszerek



# Nativ MSCT –Ca Score

Patient Tools ArteryLabel Report Image View Options Options System Help

Lex, Helene  
ID: 0020288970  
\*28-Nov-1925  
25-Jul-2000  
TA 13:35:00  
I No. 30

Lex, Helene  
ID: 0020288970  
\*28-Nov-1925  
25-Jul-2000  
TA 13:34:54

Lex, Helene  
ID: 0020288970  
\*28-Nov-1925  
25-Jul-2000  
TA 13:34:54

Artery Labels

LM LAD CX RCA Other X

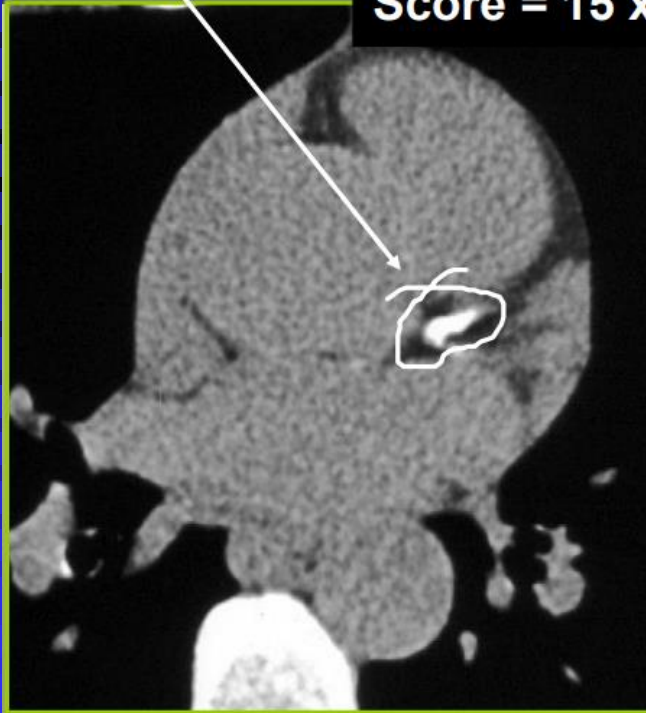
Artery	Number of lesions(f)	Mean	Peak	Area	Score
LAD	1	170.000	300.000	340.000	143.000
LM	0	0	0	0	0
RCA	0	0	0	0	0
CX	4	680.000	1200.000	1360.000	572.000
<b>Total</b>	<b>5</b>	<b>650.000</b>	<b>1500.000</b>	<b>1700.000</b>	<b>715.000</b>

Viewing  
Filming  
3D  
CaScore  
Pulmo



# Nativ MSCT – Agatston Ca Score

Area = 15 mm<sup>2</sup>  
Peak CT = 450  
Score = 15 x 4 = 60

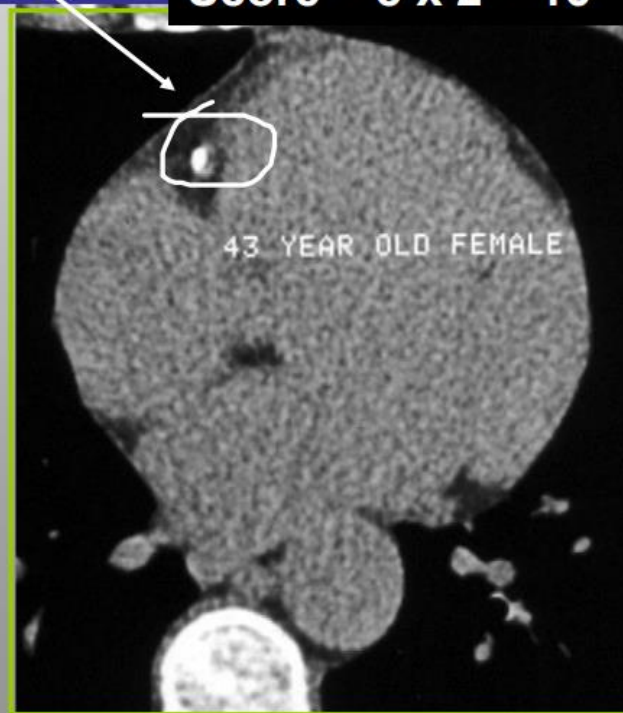

Total Score = S

**Hn x-factor  
(Agatston Scoring)**

130-199	1
200-299	2
300-399	3
>400	4

Area = 8 mm<sup>2</sup>  
Peak CT = 290  
Score = 8 x 2 = 16



Peak density (Hounsfield units), and measurement of area in each coronary

Calcium score = total area and density in each calcified lesion

Volume of Calcium is calculated



## Natív MSCT –Ca Score

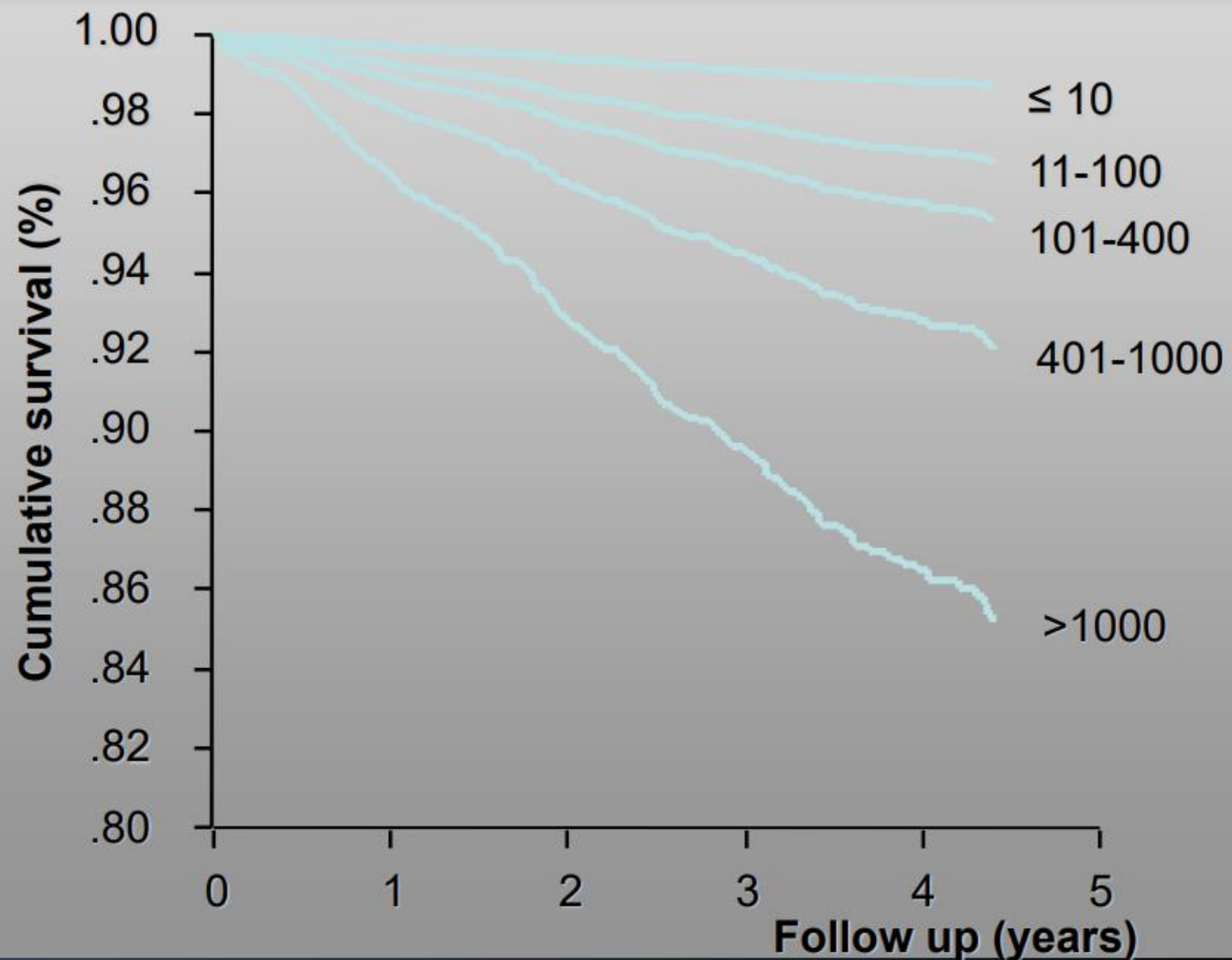
Linear scale - 4 calcium score categories:

0	no
1 - 100	mild
100 - 400	moderate
>400	severe

There is a direct correlation between Calcium score and coronary event and the probability of obstructive CAD



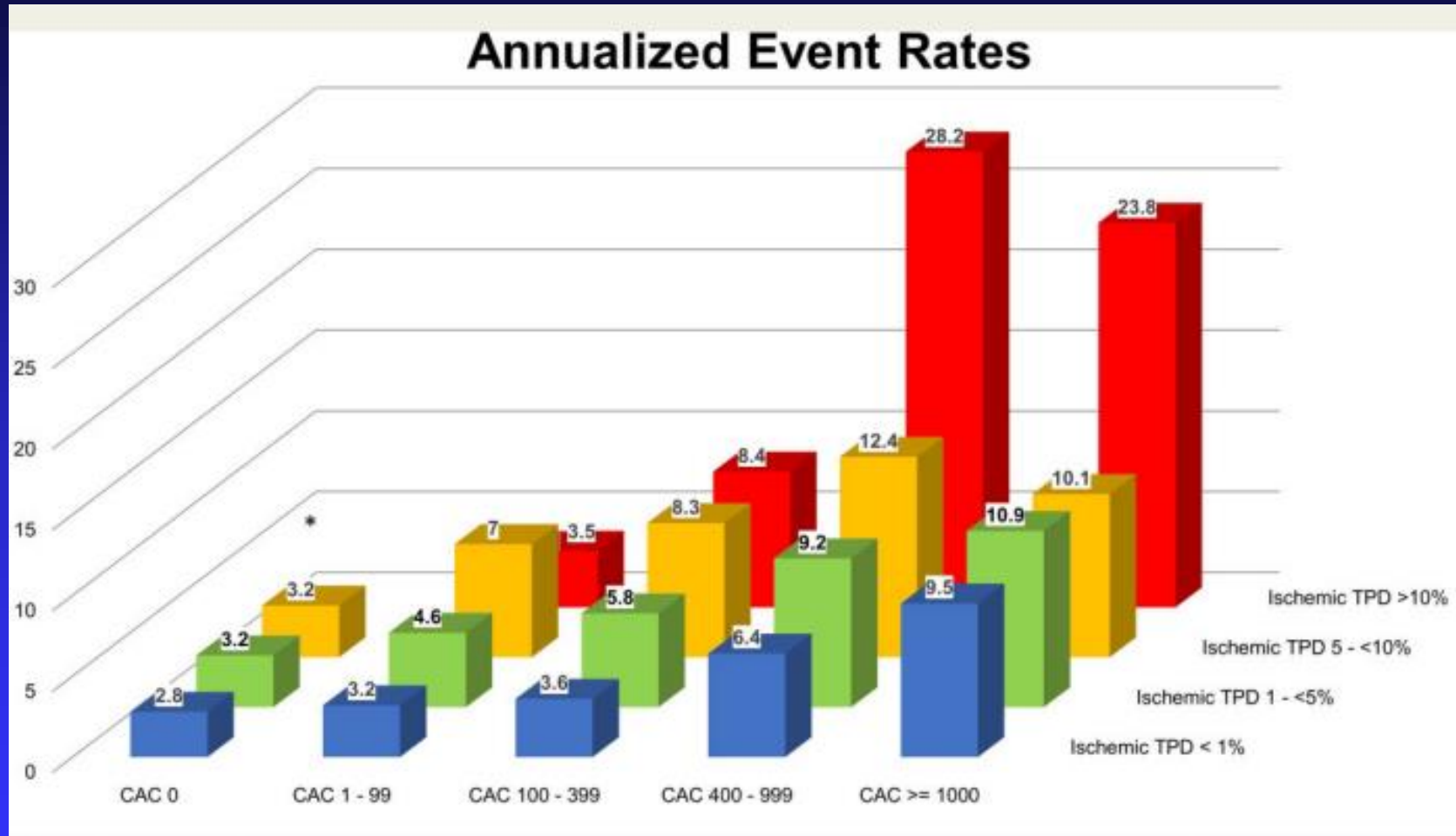
## Coronaria Arteria Calcium (CAC) Score – összesített halálozás prediktora (Risk-Unadjusted All-Cause Mortality)



Shaw LJ, et al. *Radiology*. 2003;228:826-833.



# CAC score – perfúzió és MACE



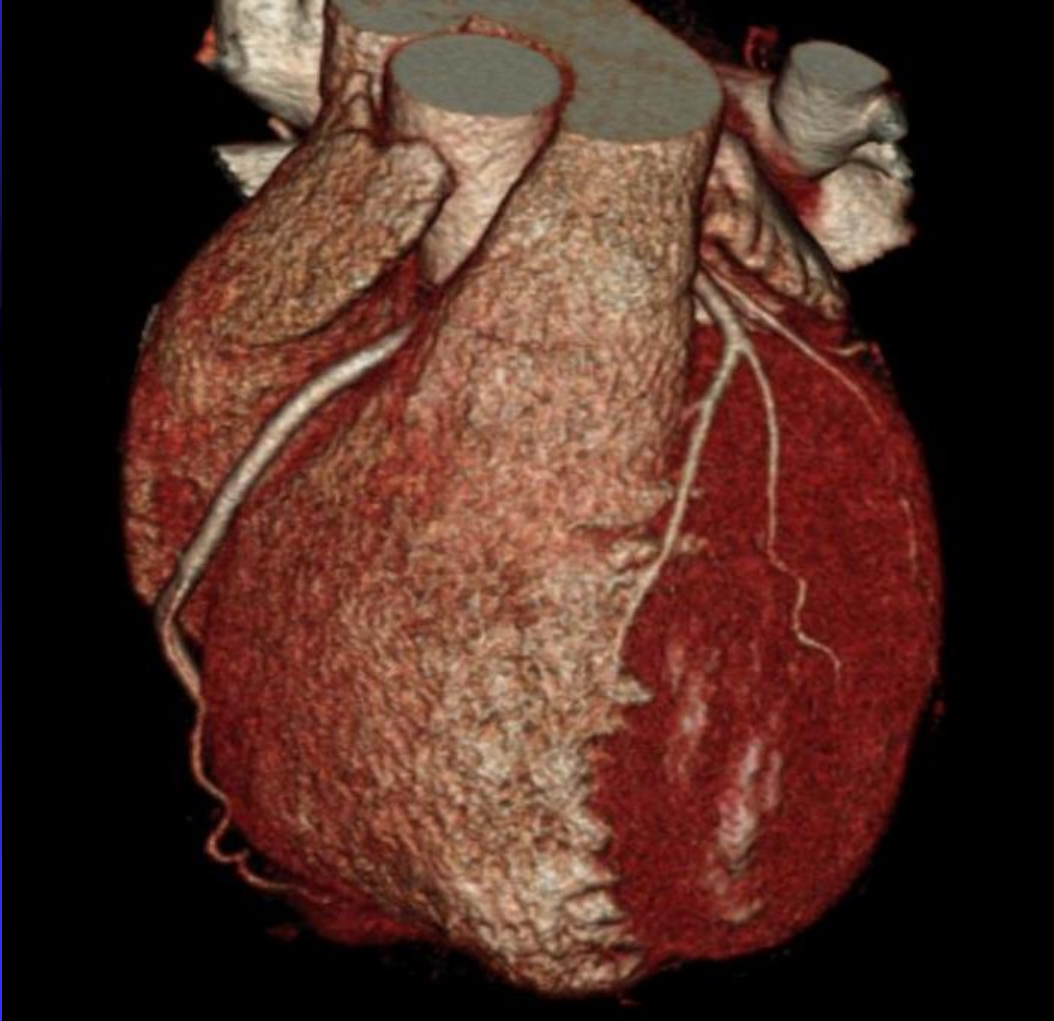
2507 patients who underwent positron emission tomography myocardial perfusion imaging. Median follow-up of 3.9 years for MACE (all-cause mortality, non-fatal MI, unstable angina or late revascularization)



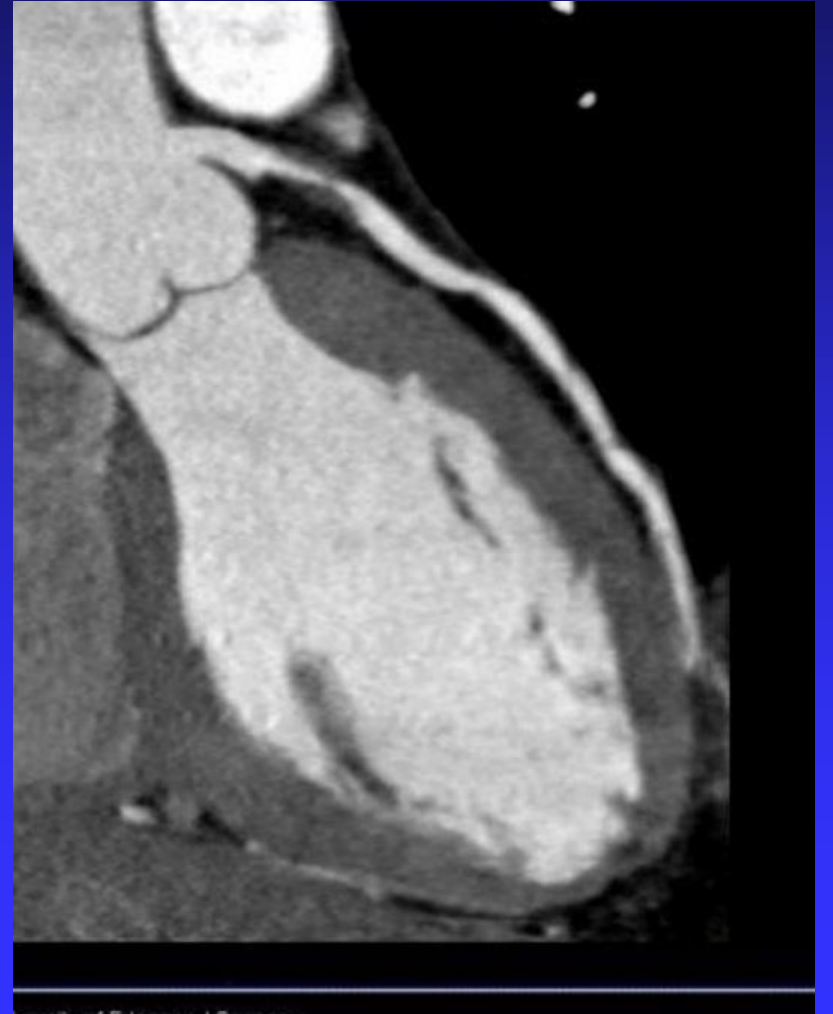

# Kontraszt MSCT

3-D Volume Rendered Image

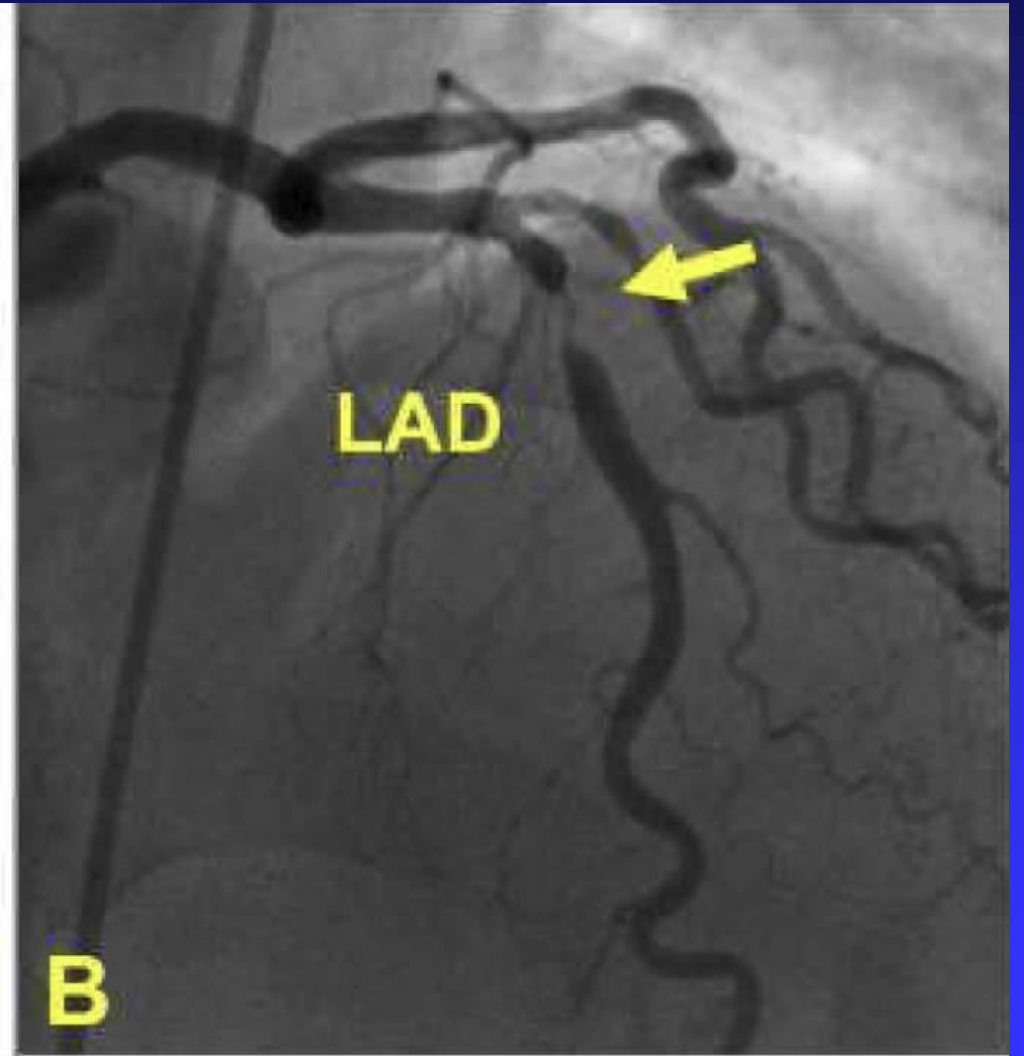
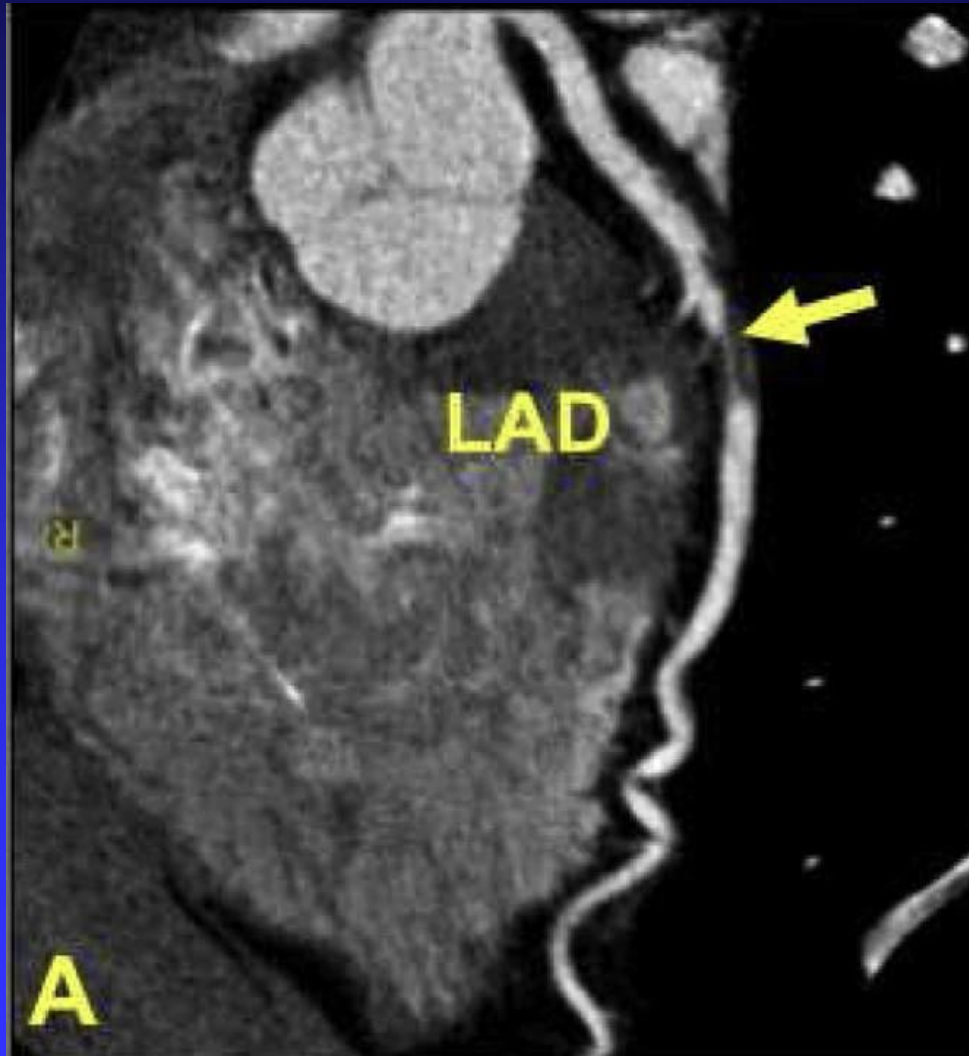


Maximum Intensity Projection



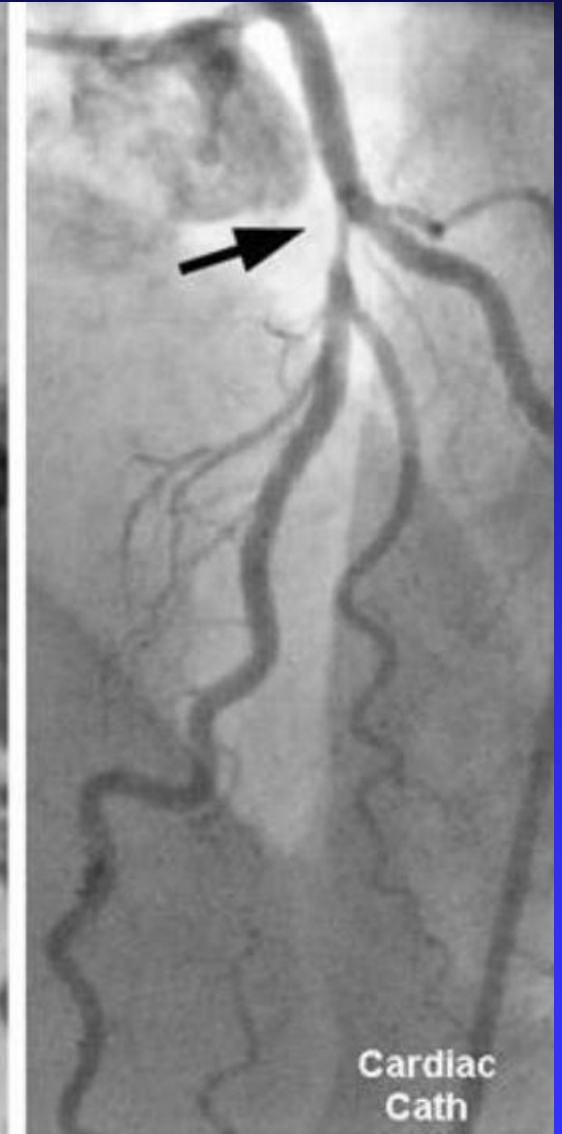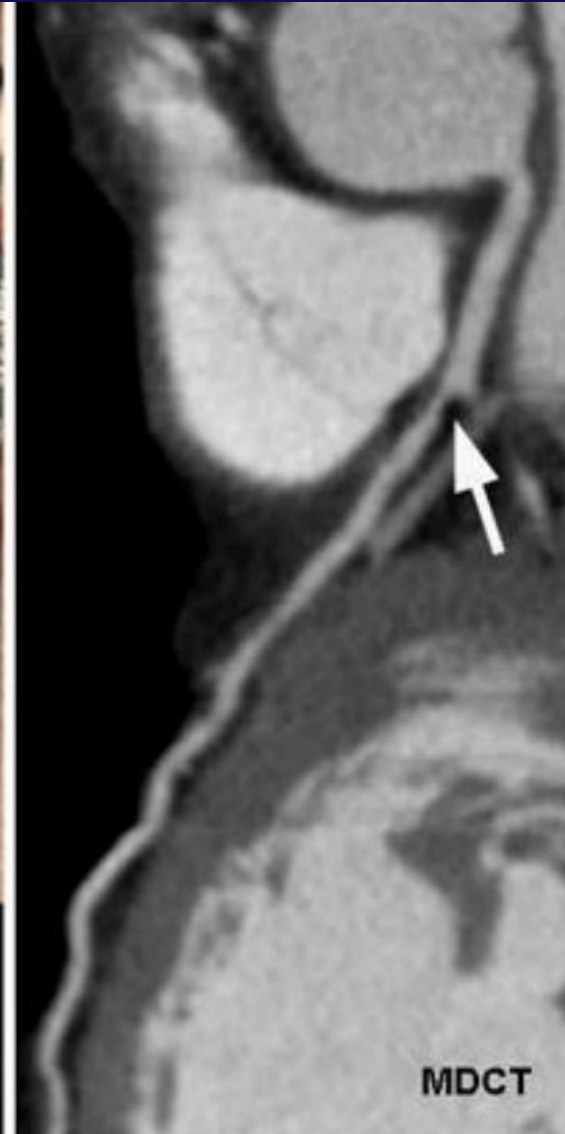

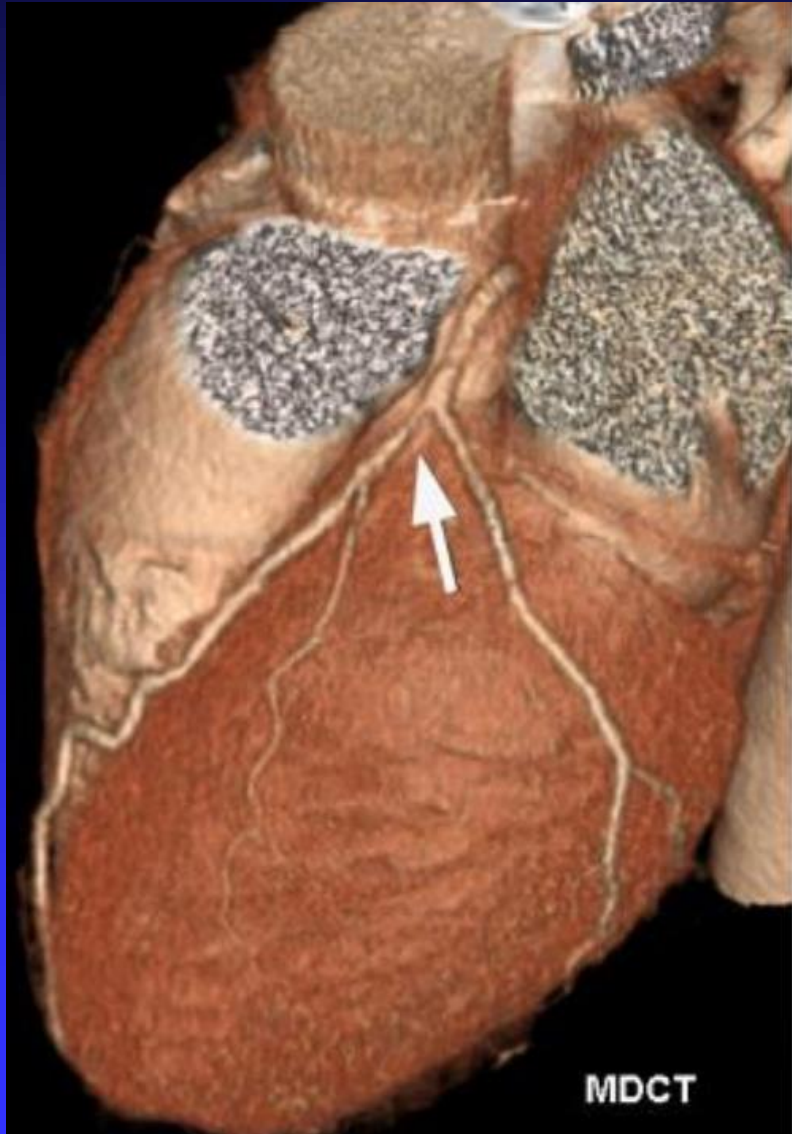
# Kontraszt MSCT és coronarographia





# Kontraszt MSCT és coronarographia

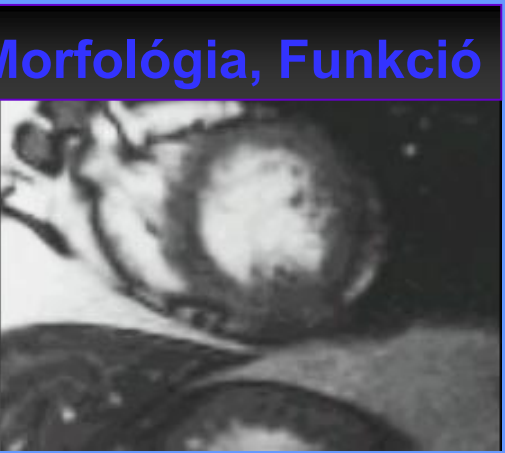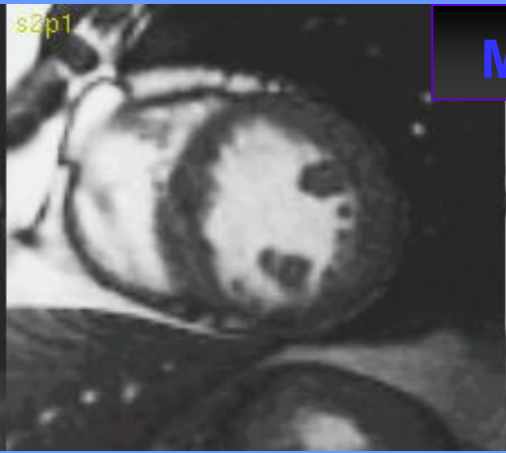

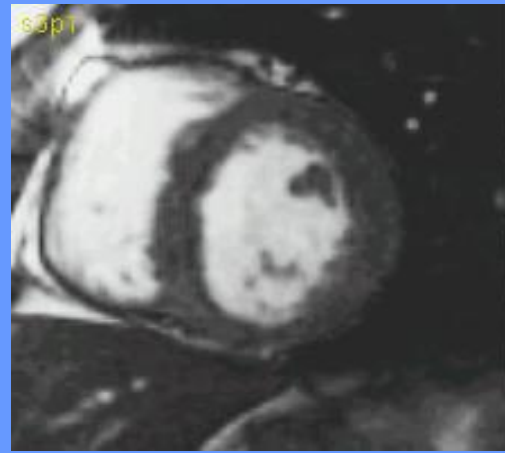


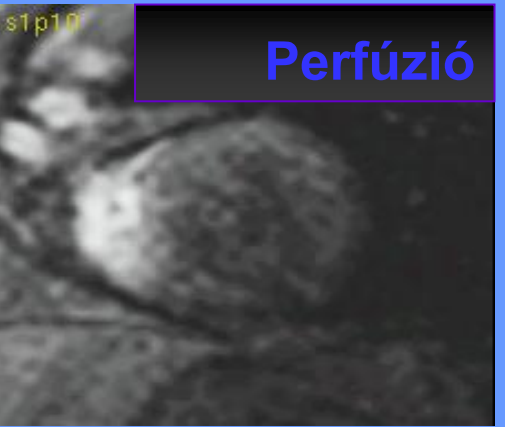
Köszönöm a figyelmet!







**Morfológia, Funkció**



**Perfúzió**



**Életképesség**



# Stressz MRI, provokálható iszkémiával

